

EDITORIAL

Methods of Differentiation of Inferior, or Other Myocardial Wall Defects From Artifacts in Myocardial Scintigraphy: The Role of Prone Positioning and/or Other Techniques

Chariklia Giannopoulou, MD, Nikolaos Papanthanasios, MD

*Nuclear Medicine Department,
“Evangelismos” Hospital, Athens,
Greece*

KEY WORDS: *single photon emission
computed tomography; prone SPECT;
coronary artery disease imaging;
perfusion artifacts*

LIST OF ABBREVIATIONS:

CAD = coronary artery disease

CT = computed tomography

LV = left ventric-le (-lar)

MPS = myocardial perfusion scintigraphy

SPECT = single photon emission
computed tomography

Correspondence to:

Chariklia Giannopoulou, MD
Nuclear Medicine Department
“Evangelismos” Hospital
45-47 Ipsilantou street,
Athens 106 76, Greece
E-mail: harisg@otenet.gr

ABSTRACT

Stress radionuclide myocardial perfusion scintigraphy (MPS) with the use of single photon emission computed tomography (SPECT) is a widely established method for the detection of coronary artery disease, patient management and patient risk stratification, as well as evaluation of revascularization results. MPS SPECT is traditionally being performed with patients in the supine position. This practice is, however, associated with various soft tissue attenuation artifacts, resulting in reduced test specificity. Various methods have been investigated to deal with this problem including the inspection of planar projection images, the integration of wall motion and wall thickening information from gated MPS, the application of transmission attenuation maps from radionuclide sources and the MPS SPECT with the patient in prone position. Most of the above methods suffer from several limitations. However, the addition of prone acquisition to traditional supine MPS SPECT has been proven to be an easy and efficient way to reduce attenuation artifacts (concerning mainly the inferior wall) leading to a significant improvement in the specificity of this imaging technique.

INTRODUCTION

Stress radionuclide myocardial perfusion scintigraphy (MPS) with the use of single photon emission computed tomography (SPECT) is a widely established method for the detection of coronary artery disease (CAD), patient management and patient risk stratification, as well as evaluation of revascularization results. The sensitivity of this test for the detection of angiographically significant (more than 50% stenosis) CAD was estimated to be 87%, while the specificity was 73%.¹ MPS SPECT has also important prognostic implications. In a large series of more than 4500 intermediate-high risk CAD patients, a normal ^{99m}Tc-Tetrofosmin study corresponded to an annualised cardiac death rate of less than 1% (in particular 0.6%).² Prior published studies reported excellent survival rates (ranging from 99.3% to 99.7%) for more than 10,000 patients

with normal ^{201}Tl or $^{99\text{m}}\text{Tc}$ -sestamibi SPECT studies.³⁻⁵

MPS SPECT is traditionally being performed with patients in the supine position. This practice is, however, associated with various soft tissue attenuation artifacts, resulting in reduced test specificity. Diaphragmatic attenuation of the inferior wall mainly in obese patients⁶ and breast attenuation of the anterior wall in females may cause false-positive inferior and anterior wall defects respectively. Various methods have been investigated to deal with this problem.

METHODS TO DECREASE PERFUSION ARTIFACTS

The inspection of planar projection images can help in identifying photon attenuation in the inferior wall due to the left hemidiaphragm, or in the anterior wall in females (breast attenuation artefact).⁷ However, relying exclusively on planar images-which are of suboptimal quality- for this purpose is likely to reduce sensitivity for the detection of true abnormalities and additional planar image acquisition makes the test extremely time consuming, mainly affecting patient throughput.

The integration of wall motion and wall thickening information from gated MPS may improve diagnostic performance of SPECT and effectively differentiates artifacts from true perfusion defects in equivocal fixed defects.⁸⁻⁹ Gated SPECT provide us with high quality myocardial perfusion images together with a considerable amount of data related to the performance of the left ventricle (LV): analysis of regional wall motion and quantification of global function by estimating LV end-diastolic volume, LV end-systolic volume, LV stroke volume, and LV ejection fraction.¹⁰ This approach has already proven useful in tissue characterization and prediction of outcome.¹¹ Choi et al⁸ found that reviewing gated images along with tomographic perfusion images in patients with equivocal fixed defects resulted in improvement in specificity (from 86% to 92%), sensitivity (from 72% to 80%) and interobserver agreement. Smanio et al⁹ demonstrated that the integration of gated cine images to rest-stress perfusion images reduced the number of borderline interpretations. However, gated SPECT is not considered a final solution because, by interpreting fixed defects as significant only when associated with abnormal contraction, true myocardial perfusion defects due to subendocardial infarction without associated contraction abnormality might be falsely attributed to soft-tissue attenuation.¹²

An alternative method to resolve attenuation artefacts is by applying transmission attenuation maps from radionuclide sources.¹³ Although this technique results in significant improvements in specificity and normalcy rates of MPS SPECT, it is limited by a number of factors: the physical decay of radionuclide source over time, hence the need for replacement, the installation of specialized hardware and software, the cost

and the limited availability. An evolution to this issue is the application of attenuation correction maps generated by X-ray sources integrated in modern hybrid SPECT-CT systems;¹⁴ however, such systems are also not widely available.

MPS SPECT WITH THE PATIENT IN PRONE POSITION

MPS SPECT with the patient in prone position (prone SPECT) is an easy and efficient way to reduce attenuation and motion artifacts and subsequently increases specificity of typical supine MPS SPECT. Due to a downward displacement of the diaphragm relative to the myocardium in the prone position, inferior wall artifacts are decreased. Moreover, the close contact of the anterior portion of the chest to the imaging table reduces patient motion. Prone imaging was initially described in 1988.¹⁵ One year later, Esquerre et al¹⁶ and Segall et al¹⁷ demonstrated that, for ^{201}Tl MPS, imaging patients in the prone position improved the specificity in evaluating inferior wall abnormalities, by minimizing diaphragmatic attenuation. Another study estimated an overall specificity and sensitivity of 80% and 93% respectively, for prone SPECT.¹⁸ The authors concluded that this approach should be considered when inferior wall defects on supine imaging pose a diagnostic dilemma and when motion on supine imaging necessitates repeat acquisition. Prone SPECT cannot, however, replace the traditional supine acquisition, because it has been reported to produce more artifactual anteroseptal defects, probably due to the closer position of the heart to the bony structures of the anterior chest wall.¹⁸ Prone SPECT should be utilised and interpreted as an adjunct to the supine stress acquisition, in order to reduce false-positive MPS findings.

A significant study by Hayes et al,¹⁹ regarding the prognostic implications of combined supine-prone SPECT was published in 2003. More than 3800 patients were included in this study. Three-hundred sixty-eight patients had normal prone and supine studies and the annual hard cardiac event rate was calculated at only 0.7% for this group. Conclusively, patients with negative results on additional prone SPECT showed a benign prognosis with a low rate of annual major adverse cardiac events (less than 1%) similar to those who had negative results on conventional supine SPECT. Thus, negative results by adding prone acquisition, not only increase specificity, but also indicate event-free survival. An invited commentary²⁰ published in the same year, advised the use of prone SPECT as a supplementary tool for conventional supine SPECT, to improve diagnostic specificity at the inferior wall.

A similar study, conducted in our department, revealed comparable results. Three-hundred eighty-six patients, without prior history of CAD were identified as having inferior only or anterior only perfusion defects. These patients were mainly men (82%) and the vast majority of the defects

(94.5%) had been noted in the inferior wall. Follow-up of 18.5 ± 6 months was achieved in 344 out of 367 patients who had been interpreted as having a normal combined supine-prone SPECT study. No major cardiac events were observed in any of these 344 patients; while only one patient of this group had an angioplasty performed 16 months post MPS. We concluded that patients with negative combined supine-prone SPECT seem to carry a low risk for subsequent major cardiac events.¹² Additional recent evidence supports the improved diagnostic performance of MPS SPECT, by adding prone acquisition. Nishina et al⁷ applied quantification analysis in polar maps of stress images of a large group of 650 patients. They found out that combined supine-prone SPECT were more accurate, as measured by the area under the curve of respective receiver-operating-characteristic (ROC) curves, than supine only and prone only SPECT in identification of $\geq 70\%$ coronary vessel stenosis. Combined SPECT improved specificity of supine SPECT from 65% to 86% and yielded higher normalcy rates in obese patients. We note that the term "normalcy rate", which is frequently mentioned in MPS studies, has been developed to correct for the test's referral bias on true specificity. Normalcy rate is used to describe the frequency of normal test results in patients with a low likelihood of CAD, to differentiate it from specificity. The same research group applied this quan-

titative combined prone-supine SPECT algorithm in a large group of female population to counteract for breast artifacts.²² Results were validated by coronary angiography. Combined supine-prone quantitative SPECT in women yielded significantly increased specificity (94%) and normalcy rates without compromising sensitivity for the detection of CAD compared with standard supine SPECT.

Prone SPECT can be performed in conjunction with supine gated SPECT, as has been shown by Berman et al.²³ This combination has been found to achieve a reasonable diagnostic accuracy, no matter if the patient is overweight or even obese. In a recent study, designed to compare computed tomography (CT)-based attenuation correction (with hybrid SPECT/CT) with prone SPECT, the latter method was found to decrease equivocal MPS findings substantially to a percentage of 18% of the total number of studies.²⁴ However, CT-based attenuation correction has been proven to be superior to prone imaging by reducing the equivocal findings even more to 11%. Bearing in mind the limitations of attenuation correction maps via SPECT/CT, namely the expensive system requirement and its relative unavailability, prone SPECT remains the most practical, feasible and efficient means of increasing MPS specificity, by reducing attenuation artefacts.

CONCLUSION

The addition of prone acquisition to traditional supine MPS SPECT has been proven to be an easy and efficient way to reduce attenuation artifacts (concerning mainly the inferior wall) and consequently increase the specificity of MPS. Prone SPECT requires only an additional acquisition of approximately 10 minutes and it can be performed on virtually any SPECT camera. It is costless, it does not implement additional hardware-software and most importantly it can be tolerated by the vast majority of patients. These reasons have rendered combined supine-prone SPECT a routine technique in our institution.

REFERENCES

1. Klocke FJ, Baird MG, Lorell BH, et al. ACC/AHA/ASNC guidelines for the clinical use of cardiac radionuclide imaging-executive summary: a report of the ACC/AHA Task Force on Practice Guidelines (ACC/AHA/ASNC Committee to Revise the 1995 Guidelines for the Clinical Use of Cardiac Radionuclide Imaging). *J Am Coll Cardiol* 2003;42:1318-1333.
2. Shaw LJ, Hendel R, Borges-Neto S, et al. Prognostic value of normal exercise and adenosine (99m)Tc-tetrofosmin SPECT imaging: results from the multicenter registry of 4,728 patients. *J Nucl Med* 2003;44:134-139.
3. Hachamovitch R, Berman DS, Shaw LJ, et al. Incremental prognostic value of myocardial perfusion single photon emis-

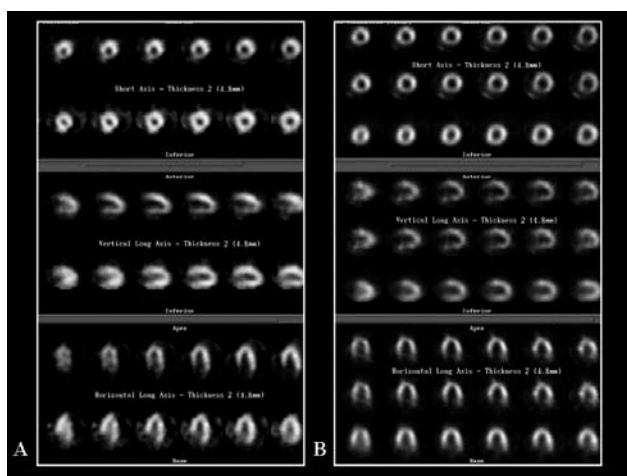


FIGURE 1. A. SPECT myocardial perfusion scan: Stress study (upper row images): Decreased sestamibi-Tc99m uptake is noted in the inferior myocardial wall. The same projection after placing the patient in prone position (lower row images): normal uptake in all myocardial walls. Inferior wall defect was due to attenuation artifact. B. SPECT myocardial perfusion scan: Stress study (upper row images): Decreased sestamibi-Tc99m uptake is noted in the inferior myocardial wall. The same projection after placing the patient in prone position (middle row images): no change in RP distribution in myocardial walls. Rest study (lower row images): increased sestamibi-Tc99m uptake in the inferior wall denotes ischemia.

PRONE POSITIONING IN MYOCARDIAL SCINTIGRAPHY

- sion computed tomography for the prediction of cardiac death: differential stratification for risk of cardiac death and myocardial infarction. *Circulation* 1998;97:535-543.
4. Groutars RG, Verzijlbergen JF, Zwinderman AH, et al. Incremental prognostic value of myocardial SPET with dual-isotope rest (201)Tl/stress (99m)Tc-tetrofosmin. *Eur J Nucl Med Mol Imaging* 2002;29:46-52.
 5. Iskander S, Iskandrian AE. Risk assessment using single-photon emission computed tomographic technetium-99m sestamibi imaging. *J Am Coll Cardiol* 1998;32:57-62.
 6. DePuey EG, 3rd. How to detect and avoid myocardial perfusion SPECT artifacts. *J Nucl Med* 1994;35:699-702.
 7. Nishina H, Slomka PJ, Abidov A, et al. Combined supine and prone quantitative myocardial perfusion SPECT: method development and clinical validation in patients with no known coronary artery disease. *J Nucl Med* 2006;47:51-58.
 8. Choi JY, Lee KH, Kim SJ, et al. Gating provides improved accuracy for differentiating artifacts from true lesions in equivocal fixed defects on technetium 99m tetrofosmin perfusion SPECT. *J Nucl Cardiol* 1998;5:395-401.
 9. Smanio PE, Watson DD, Segalla DL, et al. Value of gating of technetium-99m sestamibi single-photon emission computed tomographic imaging. *J Am Coll Cardiol* 1997;30:1687-1692.
 10. Germano G, Kiat H, Kavanagh PB, et al. Automatic quantification of ejection fraction from gated myocardial perfusion SPECT. *J Nucl Med* 1995;36:2138-2147.
 11. Sharir T, Germano G, Kavanagh PB, et al. Incremental prognostic value of post-stress left ventricular ejection fraction and volume by gated myocardial perfusion single photon emission computed tomography. *Circulation* 1999;100:1035-1042.
 12. Wagner A, Mahrholdt H, Holly TA, et al. Contrast-enhanced MRI and routine single photon emission computed tomography (SPECT) perfusion imaging for detection of subendocardial myocardial infarcts: an imaging study. *Lancet* 2003;361:374-379.
 13. Hendel RC, Corbett JR, Cullom SJ, et al. The value and practice of attenuation correction for myocardial perfusion SPECT imaging: a joint position statement from the American Society of Nuclear Cardiology and the Society of Nuclear Medicine. *J Nucl Cardiol* 2002;9:135-143.
 14. Patton JA, Delbeke D, Sandler MP. Image fusion using an integrated, dual-head coincidence camera with X-ray tube-based attenuation maps. *J Nucl Med* 2000;41:1364-1368.
 15. Segall GM, Davis MJ, Goris ML. Improved specificity of prone versus supine thallium SPECT imaging. *Clin Nucl Med* 1988;13:915-916.
 16. Esquerre JP, Coca FJ, Martinez SJ, Guiraud RF. Prone decubitus: a solution to inferior wall attenuation in thallium-201 myocardial tomography. *J Nucl Med* 1989;30:398-401.
 17. Segall GM, Davis MJ. Prone versus supine thallium myocardial SPECT: a method to decrease artifactual inferior wall defects. *J Nucl Med* 1989;30(4):548-555.
 18. Kiat H, Van Train KF, Friedman JD, et al. Quantitative stress-redistribution thallium-201 SPECT using prone imaging: methodologic development and validation. *J Nucl Med* 1992;33:1509-1515.
 19. Hayes SW, De Lorenzo A, Hachamovitch R, et al. Prognostic implications of combined prone and supine acquisitions in patients with equivocal or abnormal supine myocardial perfusion SPECT. *J Nucl Med* 2003;44:1633-1640.
 20. Lee DS, Paeng JC, Lee MC. Implication of prognostically significant negative results on prone SPECT. *J Nucl Med* 2003;44:1641-1643.
 21. Giannopoulou C, Zaromitidou E, Papathanasiou N, et al. The diagnostic and prognostic value of combined supine and prone myocardial perfusion SPECT. *Eur J Nucl Med* 2006;S81.
 22. Slomka PJ, Nishina H, Abidov A, et al. Combined quantitative supine-prone myocardial perfusion SPECT improves detection of coronary artery disease and normalcy rates in women. *J Nucl Cardiol* 2007;14:44-52.
 23. Berman DS, Kang X, Nishina H, et al. Diagnostic accuracy of gated Tc-99m sestamibi stress myocardial perfusion SPECT with combined supine and prone acquisitions to detect coronary artery disease in obese and nonobese patients. *J Nucl Cardiol* 2006;13:191-201.
 24. Malkerkeker D, Brenner R, Martin WH, et al. CT-based attenuation correction versus prone imaging to decrease equivocal interpretations of rest/stress Tc-99m tetrofosmin SPECT MPI. *J Nucl Cardiol* 2007;14:314-323.