

REVIEW

Tissue Molecular Techniques in Lymphoproliferative Disorders: Contribution to Diagnosis, Prognosis, Therapy and Follow up. Bridging Molecular Pathology with Clinical Practice

Hematopathology Department,
Evangelismos Hospital, Athens, Greece

KEY WORDS: *lymphoma; polymerase chain reaction; in situ hybridization; fluorescence chromogen in situ hybridization; molecular biology*

ABBREVIATIONS

ABL1 = V-abl Abelson murine leukemia viral oncogene homolog 1
ALK = anaplastic lymphoma kinase
BCL = B-cell lymphoma
CISH = chromogenic in situ hybridization
DLBCL = diffuse large B-cell lymphomas
DNA = deoxyribonucleic acid
FISH = fluorescence chromogen in situ hybridization
FL = follicular lymphoma
Hp = Helicobacter pylori
IGH = immunoglobulin heavy chain
ISH = in situ hybridization
MALT = mucosa-associated lymphoid tissue
MCL = mantle cell lymphoma
MYC = myelocytomatosis oncogene
MRD = minimal residual disease
NHL = non-Hodgkin lymphoma;
NPM-ALK = nucleophosmin-anaplastic lymphoma kinase
PCR = polymerase chain reaction
RNA = ribonucleic acid
WHO = World Health Organization

Correspondence to:

Maria Fameli-Pavlakis, MD, PhD,
Hematopathology Department,
Evangelismos Hospital, Athens,
Greece. Tel.: +30-210-720-1542 /
+30-210-720-1544
E-mail: famelipavlaki@yahoo.gr

*Manuscript received May 18, 2011;
Revised manuscript received June 7,
2011; Re-revised manuscript received
September 2, 2011; Accepted September
16, 2011*

Maria Fameli-Pavlakis, MD, PhD, George Kanellis, MD, PhD

ABSTRACT

Molecular data are an essential component in the study of neoplasias. The important and incumbent role of molecular pathology in clinical practice is evident in the last classification of the World Health Organization (WHO) in 2008 for the tumors of the hematopoietic and lymphatic tissues, where incorporated are all the new molecular data and entities defined by genetic criteria. It is now recognized that a genetic abnormality can be considered diagnostic for an entity. At the same time the diagnostic approach of lymphoproliferative disorders is multifactorial; morphological, immunohistochemical and genetic characteristics, along with clinical data, are required for the diagnosis.

In the hematopathology laboratory, the molecular techniques used in every day practice regarding tissues are polymerase chain reaction (PCR) and in situ hybridization (ISH) using either a fluorescence chromogen (FISH) or plain chromogenic in situ hybridization (CISH). The usefulness of these molecular techniques in lymphoproliferative disorders is to document B- or T- cell clonality, including diagnosis of lymphoma, differential diagnosis between a reactive lymphoproliferation and lymphoma, staging, follow up, and detection of early stages of a lymphoma, and to detect genetic abnormalities, numerical or structural, diagnosis of certain lymphoma subtypes encompassing distinction of subtypes within the same entity with different biological behavior, prognostic indices, and indices of response to certain therapeutic regimens.

INTRODUCTION

Molecular biology is one of the fastest growing fields of basic research. This is due to the immediate extension implied by the understanding of the gene structure of cells and the capacity of relating certain genetic loci with certain entities.¹

From the beginning, molecular technique results were so useful to pathologists

that these molecular tools were soon added to their diagnostic practice. Essentially, molecular pathology is a natural prolongation both of classical pathology of macroscopic evaluation and morphologic evaluation by hematoxylin and eosin (H&E), as well as that of immunohistochemical approach.² It is based on principles, techniques and tools of molecular biology that are applied in the clinical laboratory, transferring diagnostic utilities to the cell's nucleus and especially in its genetic material, deoxyribonucleic acid (DNA) and ribonucleic acid (RNA).³ The understanding of DNA structure has led to further studies and promotion of the idea of hybridization which is the core idea of all molecular techniques used in a clinical molecular laboratory. Especially in hematopathology, the use of molecular techniques is spreading rapidly due to the ability of biomarkers to determine molecular criteria for the diagnosis of certain entities, detect minimal residual disease (MRD) during staging or patient follow up, detect early stages or in situ lymphomas, improve prognostic certainty for patients with various lymphoma subtypes, investigate the interactions between neoplastic cells and their microenvironment, determine antigens, either genes, or functional pathways useful both for diagnosis as well as for the probable production of therapeutic targets (from gene to protein). One example is the discovery of nucleophosmin-anaplastic lymphoma kinase (NPM-ALK) translocation and the subsequent discovery in tissue of ALK-protein which is not only a biomarker of a certain lymphoma subtype (ALK+/ALK- lymphoma), but also an essential prognostic marker. Another example is the use of imatinib in the treatment of leukemia associated with the V-abl Abelson murine leukemia viral oncogene homolog 1, also known as ABL1, and other rearrangements where tyrosine kinase genes are implicated.

TISSUE MOLECULAR TECHNIQUES

Almost 80% of paraffin embedded tissue samples yield DNA suitable for PCR analysis. As a result, molecular techniques on tissue samples are used with an increasing rate in everyday practice, and refer to polymerase chain reaction (PCR), in situ hybridization (ISH) using either a fluorescence chromogen (FISH) or plain chromogenic ISH (CISH).

Important advantages of these molecular techniques include the fact that they do not depend on cellular antigen expression and are characterized by high resolution: FISH $\times 10^2$, PCR $10^4 - 10^6$ comparing to 5×10^2 of classical cytogenetics. To choose one or both techniques depends on the desired outcome. For example, when the target gene is identified, PCR is the quickest, most sensitive and specific solution. When a cytogenetic abnormality is known, but the target gene is not identified completely, then the method of choice is FISH. Also, in the case of chromosomal translocations and complex rearrangements, PCR is not chosen, because a large number

of primers are required.

POLYMERASE CHAIN REACTION (PCR)

Polymerase chain reaction (PCR) was developed in the mid 80's in California, and today is a "mature" technique with broad applications in the laboratories due to its high capacity in detecting certain genetic targets. It is a reaction that multiplies nucleic acid via DNA polymerase, hence its name. The basic principles are illustrated in Figure 1. A certain DNA sequence is selected (oncogenes, genetic mutations, etc) and with the use of short DNA sequences, called primers, and DNA polymerase, the selected target is amplified according to 3 steps, denaturation, annealing, and extension. These 3 steps define a PCR cycle which accelerates with fluctuation of temperature. The repetition of these cycles leads to the production of many copies of the target sequence, to the point that after 30-40 cycles more than 1×10^9 copies are made. The PCR product is then analyzed and visualized either in the form of bands using the heteroduplex technique or in the form of peaks using gene scanning. The whole procedure lasts 2-4 hours and today is fully automated using special machines called thermal cyclers.

There are several types of PCR: simple PCR, nested PCR, seminested PCR, reverse transcriptase PCR, real time PCR. The use of PCR spread rapidly among laboratories due to its advantages, which include high sensitivity and specificity, automation, capability of simultaneous study of multiple samples, rapid completion and capability of using archived material. Basic disadvantages of this methodology include destruction of cell morphology, existence of false negative results due to bad quality or limited DNA, improper annealing of PCR primers, etc., or false positive results due to contamination, selective amplification of other genetic regions, etc. Key factors which affect PCR specificity and sensitivity include suitable primers (complementary to the target DNA), precise compliance with each protocol, quality of DNA polymerase, avoidance of

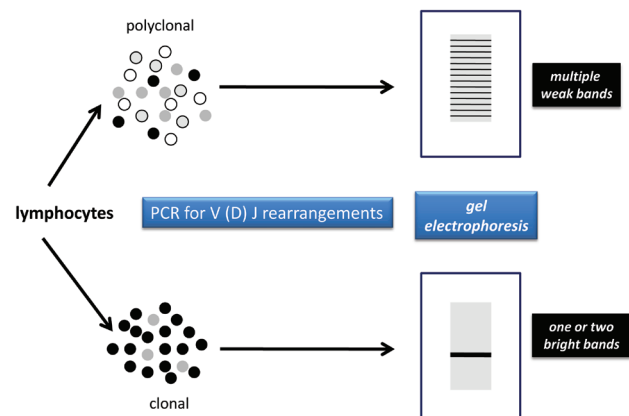


FIGURE 1. Principle for detecting monoclonal B-cell populations on tissue sections.

contaminations, quality of tissue sample (means of fixation, adequate sample). The fact that in PCR, cell morphology is not preserved, make necessary a high experience in result evaluation. A reliable evaluation requires a simultaneous use of controls (positive, negative, nonspecific), specialized personnel, collaboration of the molecular biologist with the pathologist, awareness of the procedure by the medical doctor (about technique, tissue limitations, false positive and false negative results) and the essential knowledge that clonality is not equivalent to malignancy.

IN SITU HYBRIDIZATION (ISH)

In situ hybridization (ISH) is a method of direct visualization of selected genetic targets (signal amplification methods) and is relying on the fundamental property of nucleic acids (due to the principles of complementarity of bases) to form stable dimers called hybrids. Visualization is achieved with fluorescent DNA or RNA probes (fluorescence ISH- FISH) or immune-chromogen probes (chromogenic ISH-CISH), and the signals can be amplified and processed with specific software. The procedure includes consecutive steps of denaturation and annealing with the probes being applied directly on the glass slide. The emitted visual signals are verified by microscopy (light or fluorescent) and further analysis can be made via specific software.

There are several types of ISH. In *chromogenic ISH* (CISH), the probe is tagged to a non fluorescent chromogen. There is no need for a fluorescence microscope for visualization and since the signal never fades, the slides can be kept in archive for long periods of time. In *fluorescence ISH* (FISH), the probe is tagged directly with fluorophores. In *dual color FISH* (dFISH), there is simultaneous use of two probes which emit at different wave length. Therefore, each probe emits a different color (split signal) and when they fuse they emit a third color (fusion signal) (Fig. 2) like in the case of breakpoint cluster region (BCR) Abelson murine leukemia viral oncogene homolog (ABL) (BCR-ABL). More recent techniques still in research for the time being, are the spectral karyotyping (SKY), the multiplex FISH (M-FISH), whereby multiple fluorophores are used with image analysis software to visualize all chromosomes, and comparative genomic hybridization (CGH), a variation of FISH which can detect very small additions or deletions of genetic material.

The key for the successful outcome of the procedure is the correct probe. There are probes for the detection/study of whole chromosomes, chromosome fragments, or specific genetic locus (centromeres, telomeres, etc.).

In situ hybridization is a very useful technique with many advantages. It is a quick and easy methodology which conserves cell or tissue morphology achieving correlation of molecular hybridization and tissue morphology. It can be applied on non dividing cells also with the capability for utilization of

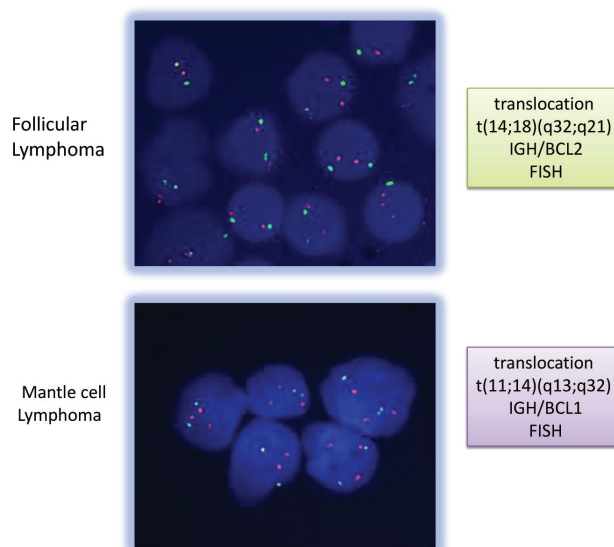


FIGURE 2. FISH analysis for detection of translocations characteristic of Follicular and Mantle cell Lymphoma respectively (pictures from the files of Hematopathology Dpt).

two probes in the same tissue section. It permits increased resolution for the identification of specific abnormalities (especially when combined with classical cytogenetics) and can highly improve diagnostic ability (for example by using a probe for the target gene and a centromeric probe) and it discriminates the true genetic amplification or deletion from chromosomal aneuploidy.

Other promising techniques are the tissue microarrays (TMA), the comparative genomic hybridization (CGH), etc. Although these techniques handle a vast amount of data, they constitute, at least for the time being, a database.

CLINICAL APPLICATIONS OF MOLECULAR TECHNIQUES IN HEMATOPATHOLOGY

Hematopathology is a field where molecular techniques and their applications in everyday practice found a suitable ground for deployment. Molecular techniques⁴ are currently applied for diagnosis, differential diagnosis, prognosis, prediction, targeted therapies and follow up. On clinical grounds these applications can be divided into three main categories (Table 1), detection of B and/or T-cell clonality, detection of chromosomal aberrations (structural or numerical) and detection of viral genomic material.

Selectively, a small number of the most recent molecular data on common lymphoproliferative disorders with clinical impact will be described below.

TABLE 1. Clinical Applications of Tissue Molecular Methodologies.

Tissue Molecular Study	Method	Applications in Clinical Practice	Examples
B/T cell clonality detection	PCR	Differential diagnosis between reactive lesions and lymphoma	Lymphoma / reactive lymphadenopathy MALT-NHL / Hp gastritis Cutaneous T-cell lymphoma / reactive T-cell hyperplasia
		Molecular diagnosis of lymphoma	Double hit lymphoma, EBV+ lymphoma of the elderly, Pediatric follicular lymphoma
		Diagnosis of in situ lymphoma	In situ follicular lymphoma (FL), In situ mantle cell lymphoma (MCL)
		Detection of early lesions	Early mycosis fungoides
		Staging	Documentation of discordant lymphomas Detection documentation of minimal residual disease (MRD) in bone marrow
		Documentation of clonal identity at different anatomical sites either simultaneously, or during relapse	Extranodal MALT lymphomas have a higher incidence of infiltration (simultaneous or subsequent) in many extranodal sites (gastrointestinal tract, lung, etc.). PCR detects the identity of the B-clone in all the infiltrated sites
Investigation for early relapse.	Early (molecular) relapse		
Detection of translocations	PCR, FISH	Documentation of lymphoma subtypes Prognostic markers Therapeutic decisions	Detection of chromosomal translocations for diagnosis of FL or MCL Detection of MYC in DLBCL DLBCL, Detection of t(11;18) translocation in gastric MALT lymphoma
Virus detection	CISH	Documentation of new entities Prognostic value	EBV+ lymphoma of the elderly EBV+ lymphoma of the elderly
Follow up of therapeutic regimens	PCR, FISH	Investigation for molecular remission	The achievement of molecular remission is an independent prognostic factor both for MCL and FL Detection of t(11;18) translocation is a more sensitive marker than B-cell clonality in patient follow up for gastric MALT lymphoma.

CISH = chromogen in situ hybridization; DLBCL = diffuse large B-cell lymphoma; EBV = Epstein-Barr virus; FISH = fluorescence in situ hybridization; FL= follicular lymphoma; Hp = Helicobacter pylori; MALT = mucosa-associated lymphoid tissue; MCL = mantle cell lymphoma; MRD = minimal residual disease; MYC = myelocytomatosis oncogene; NHL = non-Hodgkin lymphoma; PCR = polymerase chain reaction;

DIFFUSE LARGE B-CELL LYMPHOMAS (DLBCL) / WHO ICD-O 9680/3

They were the first group of lymphomas where the molecular derivations were directly related to differential diagnosis and clinical behavior, divided into three distinct subtypes, the germinal center B-cell (GCB) DLBCL, the activated B-cell (ABC) DLBCL, and the primary mediastinal DLBCL.

These subgroups have distinct molecular characteristics, different oncogenetic pathways and different clinical course.⁵⁻¹¹ It is widely accepted that the existence of chromosomal abnormalities in DLBCL are directly correlated with clinical course.

Cases that carry gene rearrangements for B-cell lymphoma (BCL) 2, BCL6, myelocytomatosis oncogene (MYC), BCL10 genes have statistically poorer prognosis than cases which share similar histological characteristics, but lack detectable gene rearrangements.¹² Also, DLBCL with particular numerical chromosomal abnormalities (i.e. a distinct genetic signature), are characterized by poor prognosis even after immunochemotherapy.¹³

PLASMABLASTIC LYMPHOMA/WHO ICD-O 9735/3

This aggressive type of lymphoma has frequent immu-

noglobulin heavy chain (IGH) / MYC translocations and additional genetic material in various chromosomal loci. The activations of the MYC locus is an important step in the pathogenetic mechanism and seems to be related to Epstein-Barr virus (EBV) infection.¹⁴

SUBTYPING LYMPHOMAS

Certain chromosomal translocations are closely related or unique to specific lymphoma types and considered as their molecular identity (Fig. 2). There follow some illustrative examples.

FOLLICULAR LYMPHOMA / WHO ICD-O 9690/3

Translocation t(14;18)(q32;q21) IGH/BCL2 is an essential element of follicular lymphoma diagnosis. It is considered to be the initial step in lymphomagenesis, however a second event (second hit) is necessary for this to happen (additions, deletions of genetic loci). Molecular studies in follicular lymphoma have shown complex interactions between follicular lymphoma cells and their microenvironment (surrounding immunologic network), directly implicated in the course of the disease.^{2,15}

MANTLE CELL LYMPHOMA / WHO ICD-O 9673/3

Translocation t(11;14)(q13;q32) IGH/BCL1 is the key component in the diagnosis of mantle cell lymphoma, an aggressive lymphoma with a rather non aggressive histologic appearance.

IN SITU LYMPHOMAS

The 2008 World Health Organization (WHO) classification of lymphomas first recognized the existence of in situ lymphomas, at least for follicular and mantle cell lymphomas. Molecular methodologies on whole tissue samples, often associated with laser capsule microdissection technology, are essential not only for the documentation of the diagnosis, but for follow up studies as well. Current data strongly suggest an indolent biological behavior of in situ lymphomas. Nevertheless, more data are still necessary for this patient group, since available information is still limited.^{2,16}

CUTANEOUS LYMPHOMAS

Cutaneous lymphoproliferative disorders of either B- or T- cell origin are among the most common cases with borderline clinical and histological features between a malignant and reactive process. Severe reactive cutaneous lymphoproliferations mimicking lymphoma are usually the result of drugs, autoimmune disorders or other factors. Documentation of

B- or T-cell clonality is a strong indicator of neoplasia and it is also capable to detect very early lymphomatous lesions (Fig. 3, Table 1).^{2,17}

THE CONCEPT OF MOLECULAR DISEASE / MOLECULAR REMISSION

The detection of molecular disease in the bone marrow during the staging of a patient with follicular lymphoma is considered a negative prognostic factor¹⁸ and a sign of increased risk for relapse (Fig. 4).¹⁹ Molecular disease may persist, despite clinical and histological remission. Nowadays it is widely accepted that molecular remission constitutes an independent prognostic factor, at least for some lymphoma types. For example molecular depression is now an independ-

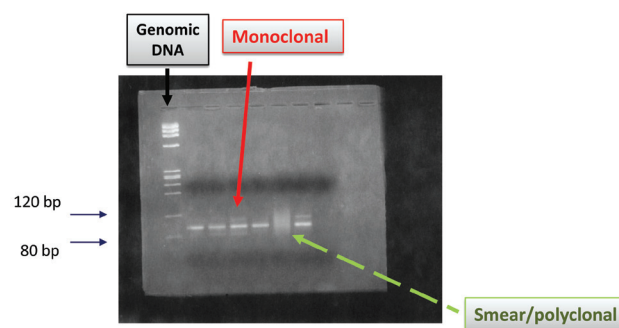


FIGURE 3. Gel electrophoresis of PCR products. Differential diagnosis between polyclonal (reactive) and monoclonal (lymphoma) process (pictures from the files of Hematopathology Dpt).

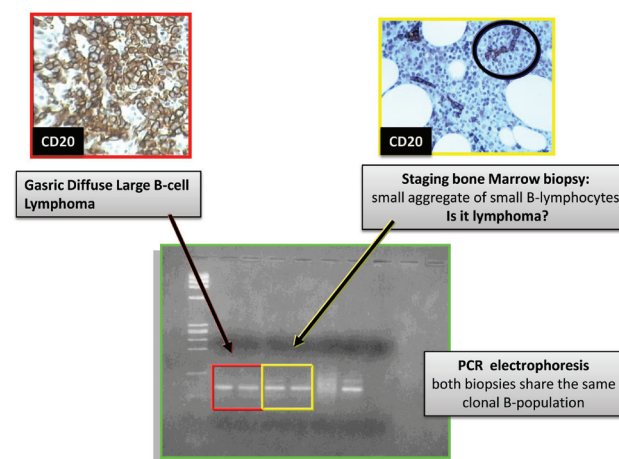


FIGURE 4. Documentation of B-cell clonality on bone marrow trephine during staging procedure for gastric Diffuse Large B-cell Lymphoma (pictures from the files of Hematopathology Dpt).

ent prognostic factor for patients with mantle cell lymphoma after immunochemotherapy.²⁰ Finally, molecular clones can be used as markers for the evaluation of therapeutic results or the detection of early recurrences.

MOLECULAR DIAGNOSIS

Some new entities are now included in the 2008 WHO classification, that require molecular criteria to be established. Certain examples are detailed below.

DOUBLE HIT LYMPHOMAS

They constitute a unique subgroup of the main group of “B-cell lymphomas, unclassifiable, with features intermediate between diffuse large B-cell lymphoma and Burkitt lymphoma” (WHO 2008) and they are characterized by concurrent IGH-BCL2 and MYC rearrangements. In fact there are no histological or immunohistochemical criteria to differentiate this subgroup. Essentially, this category can be distinguished only by molecular characteristics (FISH) and it is associated with very poor prognosis, resistance to therapy and particularly aggressive behavior. Because of these certain pertinent clinical data, today it is imperative that all DLBCL should be tested for MYC translocation, or other chromosomal aberrations.^{2,21,22}

EPSTEIN-BARR VIRUS (EBV) POSITIVE DLBCL OF THE ELDERLY

This is a new subtype of DLBCL, with EBV positivity in up to 90% of the neoplastic cells (CISH technique) and it is believed to be related to immunological abnormalities (a part of aging process). They have a very aggressive clinical course, with median survival of 2 years.^{2,23}

PEDIATRIC FOLLICULAR LYMPHOMA

Severe reactive lymphadenopathy is a common finding in children and shares certain features on histological level. Pediatric follicular lymphoma is a new subtype among follicular lymphoma types, that closely resembles a reactive process, both morphologically and immunophenotypically. Key role in the diagnosis of lymphoma process is the detection of immunoglobulin rearrangements by PCR.²

ANAPLASTIC LARGE CELL LYMPHOMA (ALCL)

Anaplastic lymphoma kinase (ALK) positive, ALK negative or variant translocations involving the ALK gene or other partner genes can be present in this type of lymphoma, but the most frequent is translocation t(2;5)(p23;q35). The presence of ALK translocations indicates a favorable prognosis compared with cases devoid of ALK translocations. Overall 5-year survival rate is 80% in ALK positive cases and 48% in

ALK negative cases. Immunostaining of the ALK with the use of monoclonal antibodies has largely replaced molecular tests and is a characteristic example of the evolution of knowledge from gene to protein level (ALK positive ALCL /ICD-O 9714/3, ALK negative ALCL /ICD-O 9702/3).²

T-CELL LYMPHOMA

Quite often it is necessary to search for possible rearrangements of the T-cell receptor with PCR, to distinguish between excessive/reactive T-cell hyperplasia and T-cell lymphoma, especially in skin lesions. Detection of certain chromosomal abnormalities (structural or numerical) with FISH (defining molecular signature) allows the enhancement of diagnostic and prognostic practice and defines possible therapeutic targets [example t(2;5) and t(5;9) for anaplastic T-cell lymphoma and peripheral T-cell lymphoma, not otherwise specified (NOS) respectively²⁴⁻²⁷].

HODGKIN LYMPHOMA

Recent studies with quantitative reverse transcription PCR (RT-PCR) have managed to determine a group of 11 genes, 4 of which concern functional pathways (cell cycle, apoptosis etc.). These genes are capable of separating stage IV patients into groups of high and low risk giving statistically significant percentages of 5-year survival free of disease.²⁸

GASTRIC MALT LYMPHOMA / WHO ICD-O 9699/3

Primary gastric lymphoma of mucosa-associated lymphoid tissue (MALT) type is an indolent lymphoma, with close relationship to pre-existing *Helicobacter pylori* (Hp) gastritis. It is often impossible to distinguish MALT lymphoma from severe gastritis both with morphology and immunohistochemistry. In such cases careful application of molecular techniques can be very helpful. Detection of B-cell clonality by PCR in a gastric biopsy suspicious, but not diagnostic, of lymphoma strongly supports a lymphoma diagnosis. It is well known that approximately 22% of gastritis samples (grade 3 and 4) may harbor monoclonal B-cell clones and that in biopsies of patients with Hp- gastritis which developed into MALT lymphoma, B-cell clonality was detected years before the diagnosis of MALT lymphoma (up to 1-2 years) and it is compatible with very early stages of the disease.²⁹⁻³¹ Thus, in borderline cases, a careful evaluation of histological, immunophenotypical and molecular criteria is crucial to establish a definite diagnosis.^{31,32}

**WHAT IS THE SIGNIFICANCE OF
B-CELL CLONALITY IN POST-
TREATMENT GASTRIC BIOPSIES?**

In approximately 50% of gastric MALT lymphoma cases, B-cell monoclonality persists after the attainment of complete response, although in some patients the clonal population gradually disappears (delayed remission).³³ In some studies patients with remission, but with persistent monoclonality were significantly more likely to relapse,³⁴ however, other studies have failed to confirm an association.³⁵

**DETECTION OF TRANSLOCATION
T(11;18)**

MALT lymphomas can be associated with certain chromosomal abnormalities, both structural and numerical.³¹ MALT lymphomas with chromosomal abnormalities have different pathogenetic pathways and as a result, different biologic behavior.³⁶

Translocation t(11;18)(q21;q21)-API-2/MALT-1 is the most common chromosomal aberration, being found in approximately 25% of gastric MALT lymphoma cases. MALT lymphomas carrying this translocation do not have any histologic or immunophenotypic feature different from translocation negative cases. Nevertheless they are characterized by advanced disease stage, they have more often spread beyond the stomach and the patients are Hp-negative. Cases which present t(11;18) are strongly associated with failure to regress after Hp eradication (all stages) and they have worse response to treatment with oral alkylating agents, but not to rituximab or cladribine. In addition, translocation positive tumors are paradoxically less likely to transform into DLBCL, and they have different gene expression profile as well as different pathogenetic mechanism.^{31,32} Finally, t(11;18) is a more sensitive marker than B-cell clonality for the monitoring of residual molecular disease.^{37,38}

PERSPECTIVE

Gene expression profiling techniques are not yet available for everyday practice in clinical laboratories. Nevertheless, gene expression profiling gives the ability to investigate changes in the expression of thousands of genes within a single cell. This technique will promote identification of novel subtypes within known lymphoma categories, new prognostic groups, as well as new insights in the pathogenetic and clinical contributions of infiltrating nonmalignant cells.

The knowledge and application of molecular techniques into the clinical laboratory is no longer a luxury; on the con-

trary, it is an essential and mandatory tool for the proper handling of patients with regard to diagnosis, prognosis and follow up. Identification of putative pathogenic agents or relatedness to other known agents and thus close to causation of disease.

Besides, the new classification of WHO includes molecular parameters, especially in lymphomas, a broad group of heterogenic malignancies with different biological and clinical behavior. Molecular pathology's aim is the detection of biomarkers of functional signature. This fact does not only concern the determination of diagnostic and prognostic factors, but also the early detection of high risk patients as well as the reevaluation of patients after treatment. Finally, molecular methodologies can be an opportunity, as well as a challenge to define possible targets for future therapeutic strategies, or to develop a therapy-oriented classification.

REFERENCES

1. Schmidt A. [Molecular markers in hematology and oncology]. *Praxis* (Bern 1994). 2010;99:1143-1152.
2. Swerdlow S, Campo E, Harris NL. *WHO Classification of Tumours of Haematopoietic and Lymphoid tissues*. Lyon: IARC Press; 2008.
3. Leonard D. *Molecular Pathology in Clinical Practice*. New York: Springer-Science+Business Media; 2007.
4. Gascoyne RD, Rosenwald A, Poppema S, Lenz G. Prognostic biomarkers in malignant lymphomas. *Leuk Lymphoma* 2010;51 (Suppl 1):11-19.
5. Savage KJ, Monti S, Kutok JL, et al. The molecular signature of mediastinal large B-cell lymphoma differs from that of other diffuse large B-cell lymphomas and shares features with classical Hodgkin lymphoma. *Blood* 2003;102:3871-3879.
6. Sehn LH. Early detection of patients with poor risk diffuse large B-cell lymphoma. *Leuk Lymphoma* 2009;50:1744-1747.
7. Westin JR, Fayad LE. Beyond R-CHOP and the IPI in large-cell lymphoma: molecular markers as an opportunity for stratification. *Curr Hematol Malig Rep* 2009;4:218-224.
8. Alizadeh AA, Eisen MB, Davis RE, et al. Distinct types of diffuse large B-cell lymphoma identified by gene expression profiling. *Nature* 2000;403:503-511.
9. Rosenwald A, Wright G, Chan WC, et al. The use of molecular profiling to predict survival after chemotherapy for diffuse large-B-cell lymphoma. *N Engl J Med* 2002;346:1937-1947.
10. Rossi D, Gaidano G. Molecular heterogeneity of diffuse large B-cell lymphoma: implications for disease management and prognosis. *Hematology* 2002;7:239-252.
11. Wright G, Tan B, Rosenwald A, Hurt EH, Wiestner A, Staudt LM. A gene expression-based method to diagnose clinically distinct subgroups of diffuse large B cell lymphoma. *Proc Natl Acad Sci U S A* 2003;100:9991-9996.
12. Tibiletti MG, Martin V, Bernasconi B, et al. BCL2, BCL6, MYC, MALT 1, and BCL10 rearrangements in nodal diffuse large B-cell lymphomas: a multicenter evaluation of a new set of fluorescent in situ hybridization probes and correlation with

- clinical outcome. *Hum Pathol* 2009;40:645-652.
13. Jardin F, Jais JP, Molina TJ, et al. Diffuse large B-cell lymphomas with CDKN2A deletion have a distinct gene expression signature and a poor prognosis under R-CHOP treatment: a GELA study. *Blood* 2010;116:1092-1104.
 14. Valera A, Balague O, Colomo L, et al. IG/MYC rearrangements are the main cytogenetic alteration in plasmablastic lymphomas. *Am J Surg Pathol* 2010;34:1686-1694.
 15. Coupland SE. The challenge of the microenvironment in B-cell lymphomas. *Histopathology* 2011;58:69-80.
 16. Cheung MC, Bailey D, Pennell N, et al. In situ localization of follicular lymphoma: evidence for subclinical systemic disease with detection of an identical BCL-2/IGH fusion gene in blood and lymph node. *Leukemia* 2009;23:1176-1179.
 17. Felcht M, Booken N, Stroebel P, Goerdts S, Klemke CD. The value of molecular diagnostics in primary cutaneous B-cell lymphomas in the context of clinical findings, histology, and immunohistochemistry. *J Am Acad Dermatol* 2011;64:135-143, 143 e131-134.
 18. van Oers MH, Tonnissen E, Van Glabbeke M, et al. BCL-2/IgH polymerase chain reaction status at the end of induction treatment is not predictive for progression-free survival in relapsed/resistant follicular lymphoma: results of a prospective randomized EORTC 20981 phase III intergroup study. *J Clin Oncol* 2010;28:2246-2252.
 19. Duhrsen U, Huttmann A, Durig J. Prognostic significance of molecular remission in follicular lymphoma. *J Clin Oncol* 2010;28:e613; author reply e614.
 20. Pott C, Hoster E, Delfau-Larue MH, et al. Molecular remission is an independent predictor of clinical outcome in patients with mantle cell lymphoma after combined immunochemotherapy: a European MCL intergroup study. *Blood* 2010;115:3215-3223.
 21. Snuderl M, Kolman OK, Chen YB, et al. B-cell lymphomas with concurrent IGH-BCL2 and MYC rearrangements are aggressive neoplasms with clinical and pathologic features distinct from Burkitt lymphoma and diffuse large B-cell lymphoma. *Am J Surg Pathol* 2010;34:327-340.
 22. Aukema SM, Siebert R, Schuurinck E, et al. Double-hit B-cell lymphomas. *Blood* 2011;117:2319-2331.
 23. Park S, Lee J, Ko YH, et al. The impact of Epstein-Barr virus status on clinical outcome in diffuse large B-cell lymphoma. *Blood* 2007;110:972-978.
 24. Mulloy JC. Peripheral T cell lymphoma: new model + new insight. *J Exp Med* 2010;207:911-913.
 25. de Leval L, Bisig B, Thielen C, Boniver J, Gaulard P. Molecular classification of T-cell lymphomas. *Crit Rev Oncol Hematol* 2009;72:125-143.
 26. Erter J, Alinari L, Darabi K, et al. New targets of therapy in T-cell lymphomas. *Curr Drug Targets* 2010;11:482-493.
 27. Piccaluga PP, Agostinelli C, Gazzola A, et al. Prognostic markers in peripheral T-cell lymphoma. *Curr Hematol Malig Rep* 2010;5:222-228.
 28. Sanchez-Espiridion B, Montalban C, Lopez A, et al. A molecular risk score based on 4 functional pathways for advanced classical Hodgkin lymphoma. *Blood* 2010;116:e12-17.
 29. Nakamura S, Aoyagi K, Furuse M, et al. B-cell monoclonality precedes the development of gastric MALT lymphoma in Helicobacter pylori-associated chronic gastritis. *Am J Pathol* 1998;152:1271-1279.
 30. Georgopoulos SD, Triantafyllou K, Fameli M, et al. Molecular analysis of B-cell clonality in Helicobacter pylori gastritis. *Dig Dis Sci* 2005;50:1616-1620.
 31. Bacon CM, Du MQ, Dogan A. Mucosa-associated lymphoid tissue (MALT) lymphoma: a practical guide for pathologists. *J Clin Pathol* 2007;60:361-372.
 32. Hummel M, Oeschger S, Barth TF, et al. Wotherspoon criteria combined with B cell clonality analysis by advanced polymerase chain reaction technology discriminates covert gastric marginal zone lymphoma from chronic gastritis. *Gut* 2006;55:782-787.
 33. de Mascarel A, Ruskone-Fourmestraux A, Lavergne-Slove A, Megraud F, Dubus P, Merlio JP. Clinical, histological and molecular follow-up of 60 patients with gastric marginal zone lymphoma of mucosa-associated lymphoid tissue. *Virchows Arch* 2005;446:219-224.
 34. Wundisch T, Thiede C, Morgner A, et al. Long-term follow-up of gastric MALT lymphoma after Helicobacter pylori eradication. *J Clin Oncol* 2005;23:8018-8024.
 35. Montalban C, Santon A, Redondo C, et al. Long-term persistence of molecular disease after histological remission in low-grade gastric MALT lymphoma treated with H. pylori eradication. Lack of association with translocation t(11;18): a 10-year updated follow-up of a prospective study. *Ann Oncol* 2005;16:1539-1544.
 36. Hamoudi RA, Appert A, Ye H, et al. Differential expression of NF-kappaB target genes in MALT lymphoma with and without chromosome translocation: insights into molecular mechanism. *Leukemia* 2010;24:1487-1497.
 37. Delsol G. [Molecular abnormalities in lymphomas]. *Bull Cancer* 2010;97:1347-1364.
 38. Levy M, Copie-Bergman C, Molinier-Frenkel V, et al. Treatment of t(11;18)-positive gastric mucosa-associated lymphoid tissue lymphoma with rituximab and chlorambucil: clinical, histological, and molecular follow-up. *Leuk Lymphoma* 2010;51:284-290.