

CASE REPORT

# Left Atrial Appendage Closure: Initial Experience with the Watchman Device

Konstantinos Toutouzas, MD, George Trantalis, MD,  
Georgios Benetos, MD, Skevos Sideris, MD,  
Konstantina Aggeli MD, Christodoulos Stefanadis, MD

First Department of Cardiology,  
Hippokratio University Hospital,  
Athens, Greece

**KEY WORDS:** atrial fibrillation;  
left atrial appendage; LAA  
closure; Watchman device; stroke;  
anticoagulation

## ABSTRACT

We herein present the first left atrial appendage (LAA) percutaneous closure procedure performed in our Institution with use of the Watchman device in an 82-year old woman with atrial fibrillation, unable to continue receiving anticoagulation therapy due to bleeding complications. A propos with this case, we discuss the data related to this therapeutic approach geared to prevent thromboembolism in patients with atrial fibrillation and contraindications to treatment with anticoagulants.

## INTRODUCTION

Atrial fibrillation (AF) is the most common cardiac arrhythmia. Its increasing incidence has serious socioeconomic consequences, because of its association with ischemic stroke.<sup>1</sup> Patients with AF have an average 5% annual risk of ischemic stroke and a 5-fold higher risk compared to an age-matched population in sinus rhythm.<sup>1</sup> The percentage of strokes attributable to AF increases steeply from ~1.5% at 50–59 years of age to more than 20% at 80–89 years of age.<sup>1</sup> Age, previous history of stroke/transient ischemic attack (TIA), hypertension, diabetes mellitus, left ventricular dysfunction and a large left atrium are factors contributing to increased risk of stroke.

The most important aspect of treatment of patients with AF is the prevention of stroke. Currently, this is best achieved with oral anticoagulation therapy, albeit with its inherent bleeding complications.<sup>2</sup> Strokes associated with AF have worse outcomes than those that occur due to other reasons. Data from the SPINAF registry shows that 15% of patients with AF suffer from silent cerebral infarcts, detected on computed tomography, the effects of which are unknown.<sup>3</sup> According to echocardiographic and other data,<sup>4</sup> the left atrial appendage (LAA) is considered to be the main site of thrombus formation and major source of consequent emboli in patients with AF. However, other important factors, including systemic atherosclerosis, coagulation disorders and increased platelet activation are also implicated in thrombus formation.<sup>5</sup> Other sources of emboli include the patent foramen ovale, the atrial septum aneurysms and the presence of atherosclerotic plaque in the proximal part of the aorta, which can be present in more than 50% of cases. From diagnosed strokes, 32% are not considered to be cardioembolic.

### ABBREVIATIONS

AF = atrial fibrillation  
INR = international normalized ratio  
LAA = left atrial appendage  
TEE = transesophageal echocardiography  
TIA = transient ischemic attack

Correspondence to:  
Konstantinos Toutouzas, MD,  
First Department of Cardiology,  
Hippokratio Hospital, Athens,  
Greece; e-mail: ktoutouz@gmail.com

Manuscript received March 11, 2014;  
Revised manuscript accepted March 28,  
2014

Conflict of Interest: none declared

Percutaneous closure of the LAA is already available in the therapeutic armamentarium of interventional cardiologists, as an alternative strategy to long-term use of oral anticoagulants, when these are ineffective or contraindicated.<sup>6</sup> The occlusion of the LAA has been included in the latest guidelines of the European Society of Cardiology (ESC) for the management of patients with AF (Class IIb, level of evidence B).<sup>7</sup>

## CASE PRESENTATION

In October 2013, at the 'Hippokraton' General Hospital of Athens, the first LAA closure procedure was performed in an 82-year old woman, through successful implantation of a Watchman device. The patient had a history of paroxysmal non-valvular AF and arterial hypertension under therapy with irbesartan. One year earlier, anticoagulation with dabigatran 110 mg bid was initiated, which caused significant skin bruising and an episode of gastrointestinal bleeding. Consequently, dabigatran was switched to acenocoumarol. However, bleeding complications occurred again, with INR 2.3 causing very large skin bruising and ocular bleeding with partial loss of vision. The remaining past medical history was significant for trochanteric fracture surgery one year earlier, whereby enoxaparin was administered for a month without complications, and for partial gastrectomy performed 13 years earlier due to stomach cancer. No history of diabetes mellitus, smoking, dyslipidemia and previous stroke or TIA was reported.

Due to the above history, LAA occlusion was decided as an alternative therapeutic option to long-term anticoagulation. Transthoracic and transesophageal echocardiography (TEE) were performed pre-procedurally to exclude the presence of thrombus within the appendage, or atrial septal defect or aneurysm, significant valvular disease, or aortic arch atheroma, and to assess left ventricular function. The estimated CHA<sub>2</sub>DS<sub>2</sub>-VASc score was 4, with an estimated annual risk of stroke 4% and the HAS-BLED score was calculated at 4.

The procedure was performed under general anesthesia under fluoroscopic and TEE guidance (Fig. 1). The atrial septum puncture system (HeartSpan - Transeptal Needle and Stylet Kit) was advanced through the right femoral vein, assisted by an 11F-sheath (Fig. 2). Intravenous heparin was administered with a target activated clotting time (ACT) > 250 sec. A 5F pigtail catheter was advanced through the long sheath and a LAA angiography was performed (view: RAO 28° - Cranial 20°) (Fig. 3-1, 3-2). Subsequently, appropriate measurements of the «neck» of the LAA were taken (Fig. 4-1, 4-2). Based on TEE, the diameter of the «neck» of the LAA was 18 mm and the presence of thrombus was excluded. Accordingly, a 24 mm Watchman device was selected. The Watchman device was launched through the dedicated 14F introducer and delivery long sheath (Watchman Access System, Boston Scientific) (Fig. 5-8). The device can be partially

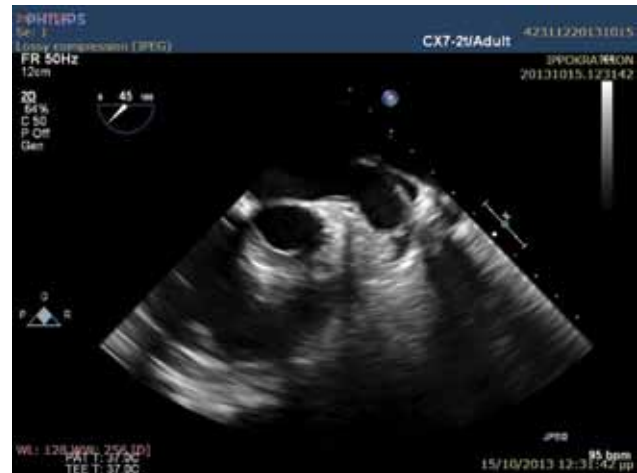

FIGURE 1. The procedure was performed under general anesthesia with fluoroscopic and transesophageal echocardiography (TEE) guidance.

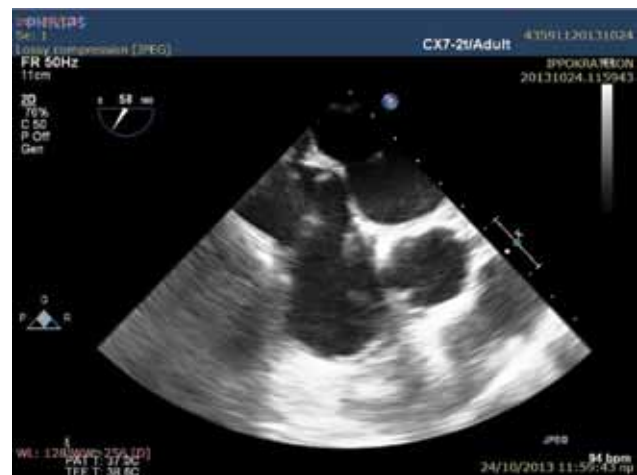

FIGURE 2. Ultrasound image of the atrial septum puncture.

recaptured and redeployed if the implant location is deemed unsatisfactory or recaptured completely if a different sized device is determined to be more suitable. After stability control was performed, the device was successfully released. The device was implanted successfully through the sheath to the predetermined position without residual communication between the LAA and the left atrium (Fig. 9). Complete occlusion of the LAA was confirmed by color-Doppler TEE (Fig. 10). A final angiogram confirmed complete occlusion and good circumferential contact of the disk of the device at the orifice of the LAA (Fig. 11). There was no pericardial effusion or other significant complication; Figure 12 shows a small residual interatrial septal communication. The total duration of the procedure was 90 minutes and 200 ml of contrast were

## NOVEL PCI TECHNIQUES

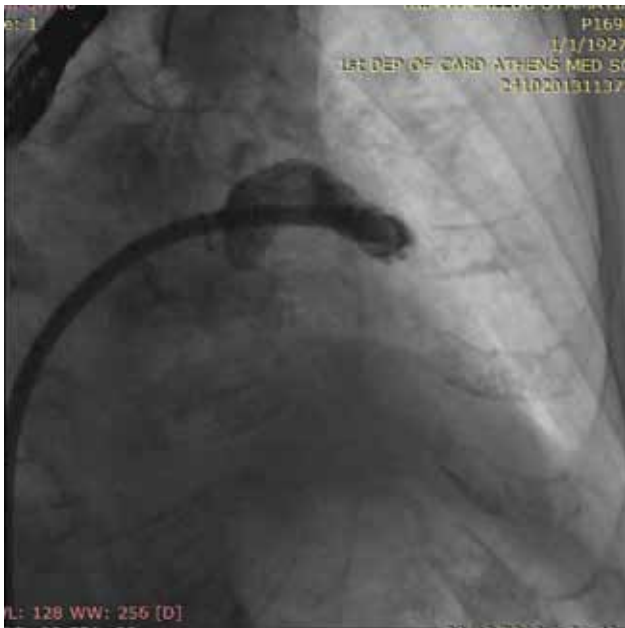

FIGURE 3-1. A 5F pigtail catheter was advanced through the introducer sheath and a LAA angiography was performed. LAA = left atrial appendage.

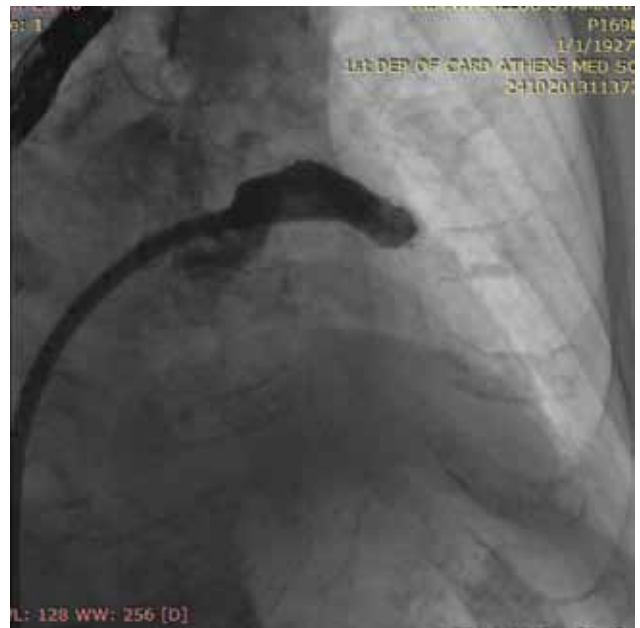

FIGURE 4-1. Angiographic view for the measurement of the “neck” of the left atrial appendage.

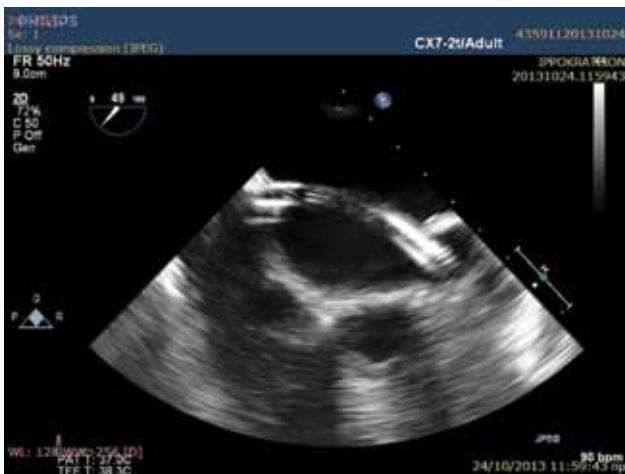

FIGURE 3-2. Ultrasound view of the 5F pigtail catheter into the left atrial appendage.

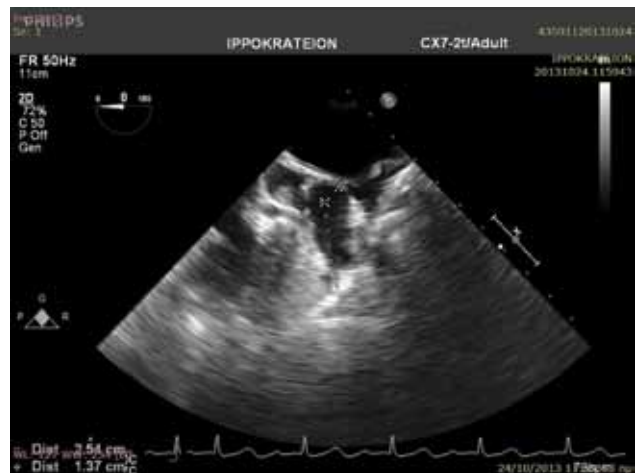

FIGURE 4-2. Ultrasound view for the measurement of the “neck” of the left atrial appendage.

employed. After 24 hours, new fluoroscopic imaging confirmed the stability and the proper position of the device (Fig. 13).

## DISCUSSION

Atrial fibrillation (AF) has been associated with endothelial dysfunction,<sup>8</sup> as documented by a decrease in plasma levels

of nitrite/nitrate and impaired blood flow, mediated by an increase of acetylcholine. Endothelial dysfunction is known to increase oxidative stress and the levels of proinflammatory agents. Atrial fibrillation is also associated with a systemic hypercoagulable state. Platelet function is enhanced with increased plasma levels of beta- thromboglobulin and platelet factor 4. Systematic markers of the activated coagulation cascade, such as the thrombin-antithrombin II complex, D- dimers, fibrinogen and fragments 1 and 2 of prothrombin are also

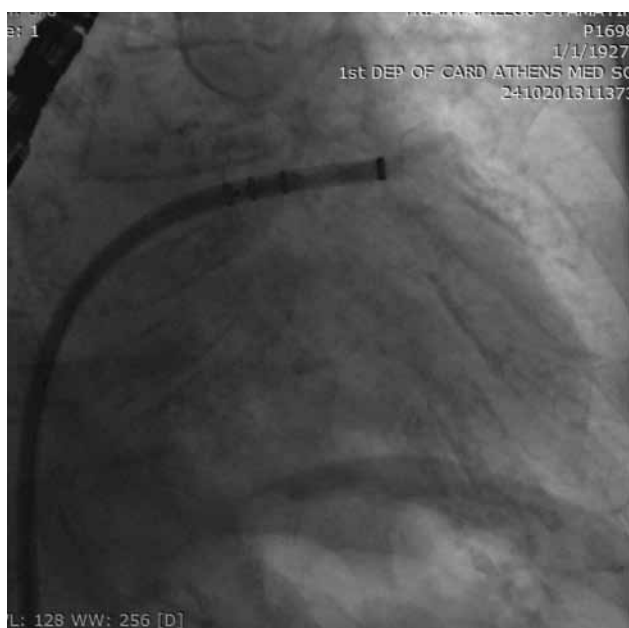

FIGURE 5. The Watchman device was launched through the dedicated 14F delivery catheter.

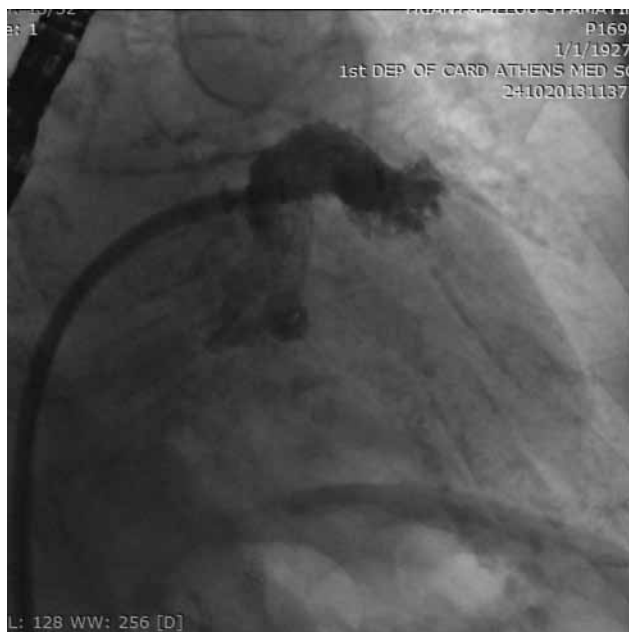

FIGURE 6. Angiographic view of the Watchman device into the left atrial appendage before the release.

elevated. In summary, patients with AF are characterized by a significant atherosclerotic burden and a systemic prothrombotic condition, that increase the likelihood of thrombosis and embolism from multiple sources except for the LAA, such as

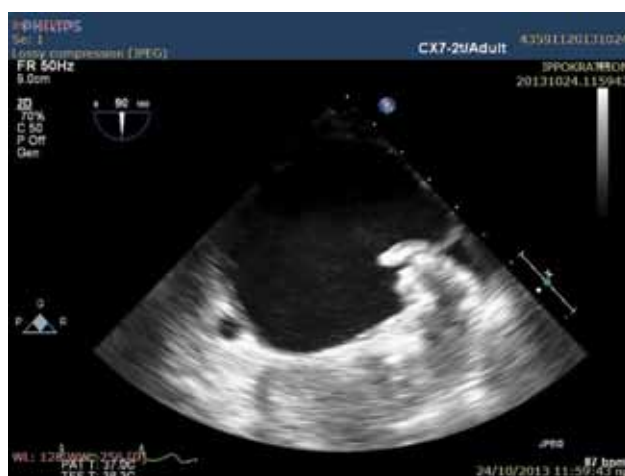

FIGURE 7. Ultrasound view of the Watchman device deployed into the left atrial appendage.

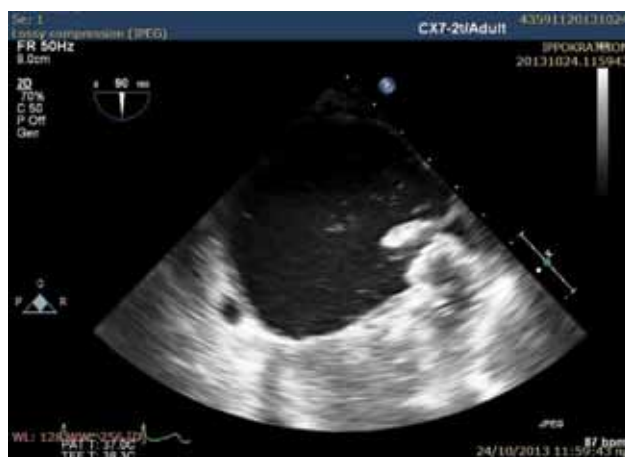

FIGURE 8. Ultrasound view of the Watchman device deployed into the left atrial appendage (LAA), after angiographic contrast injection, indicating satisfactory device position within the LAA.

the aorta, the left ventricle and cerebral vasculature.<sup>5</sup>

The left atrial appendage is an embryonic residual<sup>9</sup> of the original left atrium and is a long, tubular, trabecular structure of 2-4 cm in length, in continuity with the left atrial cavity. Its unique anatomy predisposes to in-situ thrombus formation, as more than 90% of atrial thrombi in patients with non-valvular AF are considered to originate from the LAA.<sup>4</sup> Failure of the atrium to contract during AF, results in clot formation within the LAA.

Warfarin treatment has been established<sup>2</sup> as the standard of care for the prevention of stroke in patients with AF and more than one risk factor for stroke. Compared to placebo and antiplatelet agents, warfarin reduced the rate of stroke

NOVEL PCI TECHNIQUES

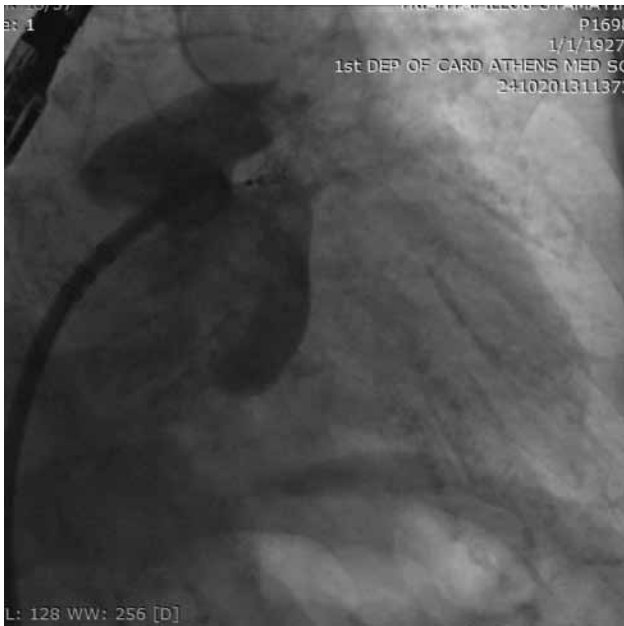

FIGURE 9. Angiographic view of the released Watchman device without residual communication between the appendage and the left atrium.

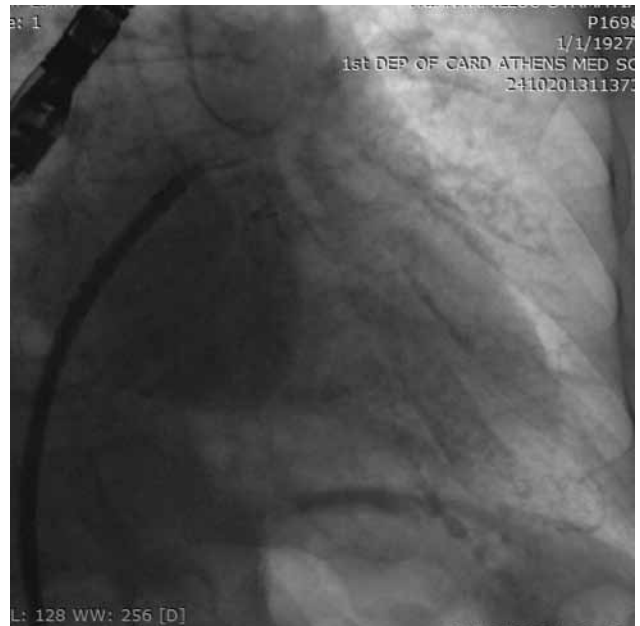

FIGURE 11. The final angiogram confirmed complete occlusion and good circumferential contact of the disk of the device at the orifice of the left atrial appendage.

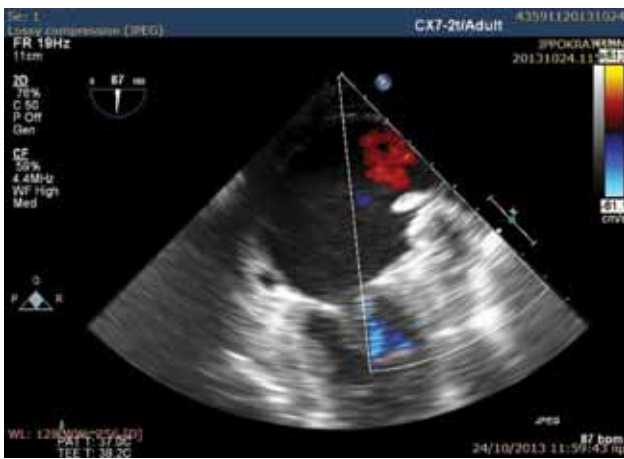

FIGURE 10. The complete occlusion of the LAA was confirmed by color-Doppler TEE. LAA = left atrial appendage; TEE= transesophageal echocardiography.

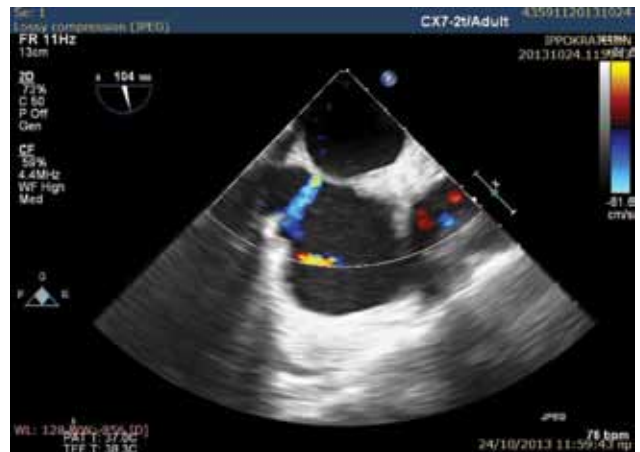
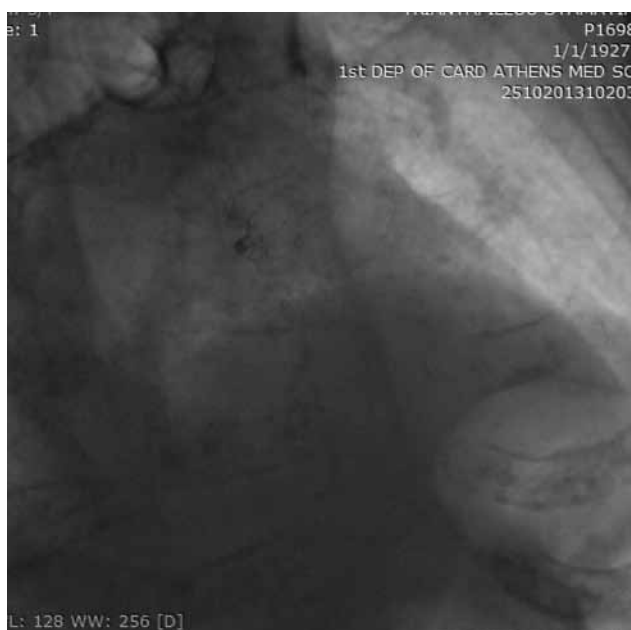
FIGURE 12. Transesophageal echocardiography with color flow Doppler indicates flow via a small residual atrial septal defect.

by 64% and 37% respectively. This is a significant therapeutic effect compared with other treatments in cardiovascular medicine. Moreover, even with an absolute increase in the risk of intracerebral hemorrhage and major bleeding of 0.2 % per year over antiplatelet therapy, warfarin still leads to a statistically significant 26% reduction of total mortality compared to placebo. Despite the proven benefit, warfarin treatment is administered only to 25%-50% of patients with AF and only

to 70% of patients who are considered 'ideal' candidates for warfarin. Furthermore, warfarin therapy may need to be discontinued at rates as high as 20% within 2.5 years of follow-up, as documented in the FRACTAL study.<sup>10</sup>

The main limitation of warfarin is the concern of bleeding and this often prevents its use in potentially suitable patients. It has been reported that patients are within the therapeutic range in only 50% - 68% of the time monitored.<sup>11</sup> The relationship between INR fluctuations and their consequences

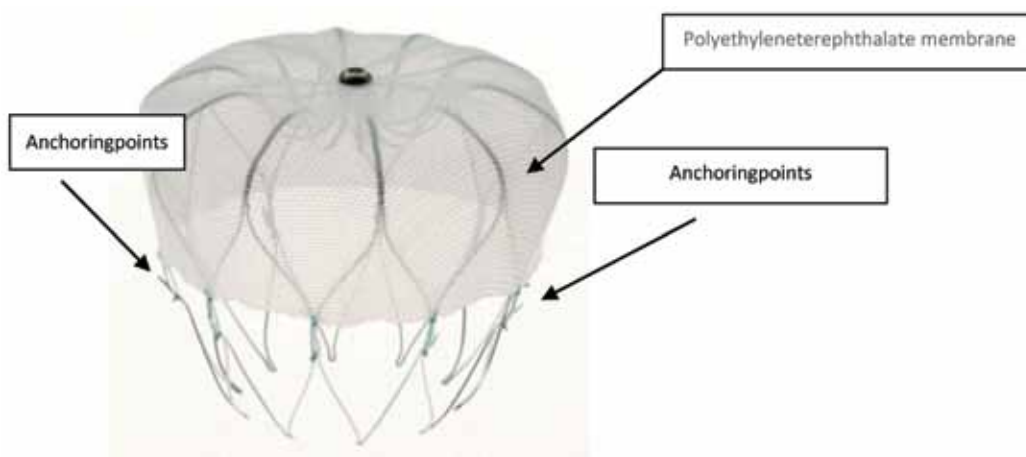


**FIGURE 13.** After 24 hours new fluoroscopic imaging confirmed the stability and the proper position of the device.

are well documented, with low INR leading to an increased risk of stroke and high INR associated with an increased risk of bleeding.<sup>11</sup> Hence the interest in alternative strategies has increased, including the use of devices which potentially occlude the LAA from the rest of the left atrial cavity. Such a device is the WATCHMAN device<sup>5,12-15</sup> (Fig. 14), which is introduced percutaneously through the femoral vein, and via transseptal puncture the device is implanted into the LAA, under fluoroscopic and transesophageal ultrasound guidance.

The Watchman device was evaluated in the PROTECT AF study,<sup>12-15</sup> a multicenter, randomized noninferiority trial of LAA closure with the Watchman device versus standard warfarin treatment. Consecutive patients (n=707) with paroxysmal, persistent or permanent non-valvular AF and CHADS<sub>2</sub> score  $\geq 1$  were randomized in a 2:1 ratio to those who received the Watchman device plus short warfarin therapy (45 days) and to those who received conventional warfarin treatment. According to the study protocol, patients randomized to the device would receive therapeutic heparin during implantation (ACT > 250 s), followed by warfarin for 45 days after the procedure, aspirin and clopidogrel for 6 months after randomization and subsequent long-term monotherapy with aspirin. Exclusion criteria included contraindications to warfarin, comorbidities, except for AF requiring chronic use of warfarin, presence of thrombus in the LAA, patent foramen ovale with presence of atrial septum aneurysm and right to left communication, mobile atheroma in the aorta, and symptomatic carotid artery disease.

The Watchman device has also been evaluated in the CAP registry, which had the same inclusion and exclusion criteria as the PROTECT AF study.<sup>12</sup> The primary efficacy endpoint was the combination of the occurrence of ischemic and hemorrhagic stroke, cardiovascular or unexplained death, and systemic embolism. The primary safety endpoint consisted of life-threatening bleeding, such as intracranial hemorrhage and gastrointestinal bleeding requiring transfusion and procedure-related complications, such as stroke associated with the procedure, pericardial effusion requiring intervention and device embolization, requiring retrieval. During a mean follow-up of 18 months, the rates of the primary efficacy endpoint of cardiovascular death, stroke or systemic embolism were 3.0 events per 100 patient-years in the device group vs 4.9 in the control group (RR: 0.62 and 95% confidence interval



**FIGURE 14.** The Watchman device consists of a self-expandable mesh with a nitinol frame and polyethylene terephthalate (PET) membrane cap; comes in 21, 24, 27, 30, 33 mm diameter sizes; it has 10 active fixation anchors for stability and retention.<sup>14</sup>

Bayesian 0.35-1.25). Hence, the device did not appear inferior to warfarin therapy. The incidence of ischemic stroke and systemic embolism was not significantly higher in the device than in the control group, but the number of events was small and a real difference between the groups cannot be excluded. Cardiovascular or death from any cause and hemorrhagic stroke was significantly less frequent in the device than in the control group. The incidence of any stroke and all-cause mortality did not differ significantly between the two groups. The stroke event rates were 2.6 events per 100 patient-years in the device group versus 3.5 events per 100 patient-years in control group (relative risk 0.74 with 95% CI 0.36 – 1.76). The incidence of ischemic stroke was 50% higher in the device group (3.0% versus 2.0 %), partly due to events that occurred early after implantation of the device. The primary safety endpoint<sup>5</sup> (composite of major bleeding or complications related to the procedure) occurred more frequently in the device than in the control group (RR: 1.69 with 95% CI 1.01 to 3.19). Most adverse events occurred early in the device group compared with the control group. During the periprocedural period in the device group, approximately one in 20 patients required drainage of pericardial effusion and one in 50 required open heart surgery.

Of the 449 implantation procedures, 408 were successful, 12.3% of patients experienced serious complications, such as pericardial effusion requiring drainage or surgery (5%) and acute stroke due to air embolism or thrombus (1.1%). In 4 patients the device subsequently had to be removed because of embolization or sepsis. Of notice, only two thirds of patients in the control group remained within the therapeutic range of INR, reflecting the difficulties associated with the use of warfarin even in a controlled environment of a clinical trial. In the CAP registry<sup>12</sup> there was a significant reduction in the incidence of procedure-related events within 7 days of the procedure (3.7% versus 7.7% in PROTECT-AF,  $p=0.007$ ). Accordingly, the rate of serious pericardial effusion within the first 7 days of implantation, which represented over 50% of primary safety endpoints in PROTECT AF, was lower in CAP registry (5.0% vs 2.2%, respectively,  $p = 0.019$ ). Similarly, there was a reduction in the incidence of strokes of the first study (PROTECT AF) in the second recording (CAP) (0.9% vs 0%;  $p= 0.039$ ). As with all invasive procedures, there was a significant improvement in the safety of Watchman device implantation in LAA with the increasing experience of the operators.

LAA closure can potentially prevent strokes in AF on the long term, but still lacks definitive proof that it is effective and safe. Given the extent of atherosclerotic plaques in some patients with AF, and the presence of a systemic disorder of coagulation and platelet function in most high-risk patients, a local approach to the LAA occlusion alone may not be sufficient. Although recent results with percutaneous closure device is promising, evidence of efficacy and safety are insuf-

ficient to recommend this approach for each patient, except for those in whom long-term warfarin therapy is absolutely contraindicated. Further large randomized studies are necessary. But even today, oral anticoagulants remain the standard of care for preventing stroke in patients with AF.

## REFERENCES

1. Wolf PA, Abbott RD, Kannel WB. Atrial fibrillation as an independent risk factor for stroke: the Framingham Study. *Stroke* 1991;22:983-988.
2. Ezekowitz MD, Bridgers SL, James KE, et al. Warfarin in the prevention of stroke associated with nonrheumatic atrial fibrillation. Veterans Affairs Stroke Prevention in Nonrheumatic Atrial Fibrillation Investigators. *N Engl J Med* 1992;327:1406-1412.
3. Ezekowitz MD, James KE, Nazarian SM, et al. Silent cerebral infarction in patients with nonrheumatic atrial fibrillation. The Veterans Affairs Stroke Prevention in Nonrheumatic Atrial Fibrillation Investigators. *Circulation* 1995;92:2178-2182.
4. Blackshear JL, Odell JA. Appendage obliteration to reduce stroke in cardiac surgical patients with atrial fibrillation. *Ann Thorac Surg* 1996;61:755-759.
5. Whitlock RP, Healey JS, Connolly SJ. Left atrial appendage occlusion does not eliminate the need for warfarin. *Circulation* 2009;120:1927-1932.
6. Sick PB, Schuler G, Hauptmann KE, et al. Initial worldwide experience with the WATCHMAN left atrial appendage system for stroke prevention in atrial fibrillation. *J Am Coll Cardiol* 2007;49:1490-1495.
7. Camm AJ, Lip GY, De Caterina R, et al. 2012 focused update of the ESC Guidelines for the management of atrial fibrillation: an update of the 2010 ESC Guidelines for the management of atrial fibrillation. Developed with the special contribution of the European Heart Rhythm Association. *Eur Heart J* 2012;33:2719-2747.
8. Guo Y, Lip GY, Apostolakis S. Inflammatory biomarkers and atrial fibrillation: potential role of inflammatory pathways in the pathogenesis of atrial fibrillation-induced thromboembolism. *Curr Vasc Pharmacol* 2013 Oct 3. [Epub ahead of print]
9. Cabrera JA, Saremi F, Sanchez-Quintana D. Left atrial appendage: anatomy and imaging landmarks pertinent to percutaneous transcatheter occlusion. *Heart* 2014 Mar 6. doi: 10.1136/heartjnl-2013-304464. [Epub ahead of print]
10. Reynolds MR, Shah J, Essebag V, et al. Patterns and predictors of warfarin use in patients with new-onset atrial fibrillation from the FRACTAL Registry. *Am J Cardiol* 2006;97:538-543.
11. Dlott JS, George RA, Huang X, et al. A national assessment of warfarin anticoagulation therapy for stroke prevention in atrial fibrillation. *Circulation* 2014 Feb 3. [Epub ahead of print]
12. Reddy VY, Holmes D, Doshi SK, Neuzil P, Kar S. Safety of percutaneous left atrial appendage closure. Results from the Watchman Left Atrial Appendage System for Embolic Protection in Patients with AF (PROTECT AF) clinical trial and the Continued Access Registry. *Circulation* 2011;123:417-424.

13. McCabe JHD, Kinsella AJ, Tobin WO. Left atrial appendage occlusion in non-valvular atrial fibrillation. *Lancet* 2009;374: 504-506.
14. Holmes DR, Reddy VY, Turi ZG, et al, for the PROTECT AF Investigators. Percutaneous closure of the left atrial appendage versus warfarin therapy for prevention of stroke in patients with atrial fibrillation: a randomised non-inferiority trial. *Lancet* 2009;374: 534-42.
15. Reddy VY, Doshi SK, Sievert H, et al; PROTECT AF Investigators. Percutaneous left atrial appendage closure for stroke prophylaxis in patients with atrial fibrillation: 2.3-year follow-up of the PROTECT AF (Watchman Left Atrial Appendage System for Embolic Protection in Patients with Atrial Fibrillation) Trial. *Circulation* 2013;127:720-729.