

CASE REPORT

Atrioventricular Conduction Disturbances in Hyperthyroidism

Skevos Sideris, MD¹, Georgios Benetos, MD², Konstantinos Gatzoulis²,
Dimitris Tousoulis, MD², Ioannis Kallikazaros, MD¹

ABSTRACT

A 73-year-old man was referred from another hospital to our department for permanent pacemaker implantation due to persistent (more than 3 days) complete atrioventricular (AV) block. His past medical history included history of hyperthyroidism under treatment with carbimazol 2.5 mg once daily. On admission, serum thyroxin stimulating hormone concentration was <0.01 $\mu\text{IU/ml}$ (normal 0.35–4.95 $\mu\text{IU/ml}$). Antithyroid drug treatment was intensified. Five days after admission complete heart block persisted on ECG, but 1 week later the ECG revealed a junctional rhythm, which resolved to first degree AV block on the tenth day of hospitalization and the patient was discharged. Subsequent follow up at 3 months after discharge with 24-hour Holter recording, revealed normal sinus rhythm without any conduction disturbances.

¹Department of Cardiology,
Hippokration Hospital, Athens, Greece
²First Department of Cardiology,
Hippokration Hospital, Athens Medical
School, Athens, Greece

KEY WORDS: heart block;
hyperthyroidism; atrioventricular
conduction disturbance

INTRODUCTION

Cardiovascular manifestations of hyperthyroidism include sinus tachycardia, atrial fibrillation, angina-like symptoms and heart failure. Impaired atrioventricular (AV) conduction is a less well-known complication of hyperthyroidism. Here we present a patient with hyperthyroidism and AV conduction disturbance as the sole finding from the cardiovascular system.

ABBREVIATIONS

AV = atrioventricular
ECG = electrocardiogram
TSH = thyroid stimulation hormone

CASE PRESENTATION

A 73-year-old man was referred from another hospital to our department for permanent pacemaker implantation due to persistent (more than 3 days) complete AV block. The patient began to have palpitations and progressive weakness one week before his admission. No syncope was mentioned. His medical history included arterial hypertension treated with enalapril/hydrochlorodiazide and hyperthyroidism under treatment with carbimazol 2.5 mg once daily.

On admission the patient was hemodynamically stable. Blood pressure was 170/70 mmHg and his pulse regular at 43 beats/min. His temperature was 37.8°C. The remainder of his clinical examination was unremarkable. The electrocardiogram (ECG) revealed complete AV block with a heart rate at 43 beats/min and narrow QRS com-

Correspondence to:
Skevos Sideris, MD, Department of
Cardiology, Hippokration Hospital,
Athens; Greece;
E-mail: skevos1@otenet.gr
Manuscript received April 27, 2014;
Revised manuscript received September
25, 2014; Accepted September 29, 2014

Conflict of Interest: none declared

plexes (Fig. 1). Echocardiography revealed only mild mitral insufficiency. We did not consider temporary transvenous pacemaker due to patient's hemodynamic stability.

Laboratory examination showed a hemoglobin of 12.2 g/dl, white blood cell count of $5.400/\text{mm}^3$, an erythrocyte sedimentation rate of 114 and a troponin value of 0.01 ng/ml. Serum free thyroxin concentration was 1.61 ng/dl (normal 0.70-1.48 ng/dl). Serum thyroxin stimulating hormone (TSH) concentration was $<0.01 \mu\text{IU/ml}$ (normal 0.35-4.95 $\mu\text{IU/ml}$). Antithyroid antibodies were positive (against thyroglobulin-anti-TG: 47.29 IU/ml with normal range $<4.11 \text{ IU/ml}$; antithyropoxidase-anti-TPO: 27.99 IU/ml with normal range $<5.61 \text{ IU/ml}$). The other biochemical parameters including auto-antibodies belonging to connective tissue disorders were negative. Blood and urine cultures for common bacteria and serology for varicella zoster virus and toxoplasma were also negative. Chest radiograph was unremarkable.

Antithyroid treatment was intensified. Body temperature returned to normal. Five days after admission to our department complete heart block persisted in ECG (Fig. 2). One week later the ECG revealed a junctional rhythm (Fig. 3), which resolved to first degree AV block (Fig. 4) on the tenth day of hospitalization and the patient was discharged.

Subsequent follow up 3 months after discharge with 24-hour Holter recording revealed normal sinus rhythm without any conduction disturbances (Fig. 5).

DISCUSSION

Hyperthyroidism predictably increases heart rate and poses a high risk for atrial fibrillation. These effects are mainly mediated through direct nuclear actions of thyroid hormones on the cardiac myocyte.¹ Although AV disturbances are not generally recognized as cardiovascular complications of thyrotoxicosis, several cases of complete heart block and hyperthyroidism have been reported in the literature.²⁻¹¹ Some patients have additional risk factors, such as infectious diseases, coexisting heart disease, electrolyte imbalances¹² or drug use.¹³ In others, however, hyperthyroidism is the only recognizable underlying disease and correction of thyroid disease restores normal AV conduction.¹⁴⁻¹⁶ Suggested mechanisms of this effect include a) an autoimmune response, causing infiltration of the cardiac conduction pathway;¹⁷ b) direct effect of thyroid hormones to be responsible for the conduction disturbance;¹⁸ c) hyperthyroidism triggered hypervagotonia.¹⁹

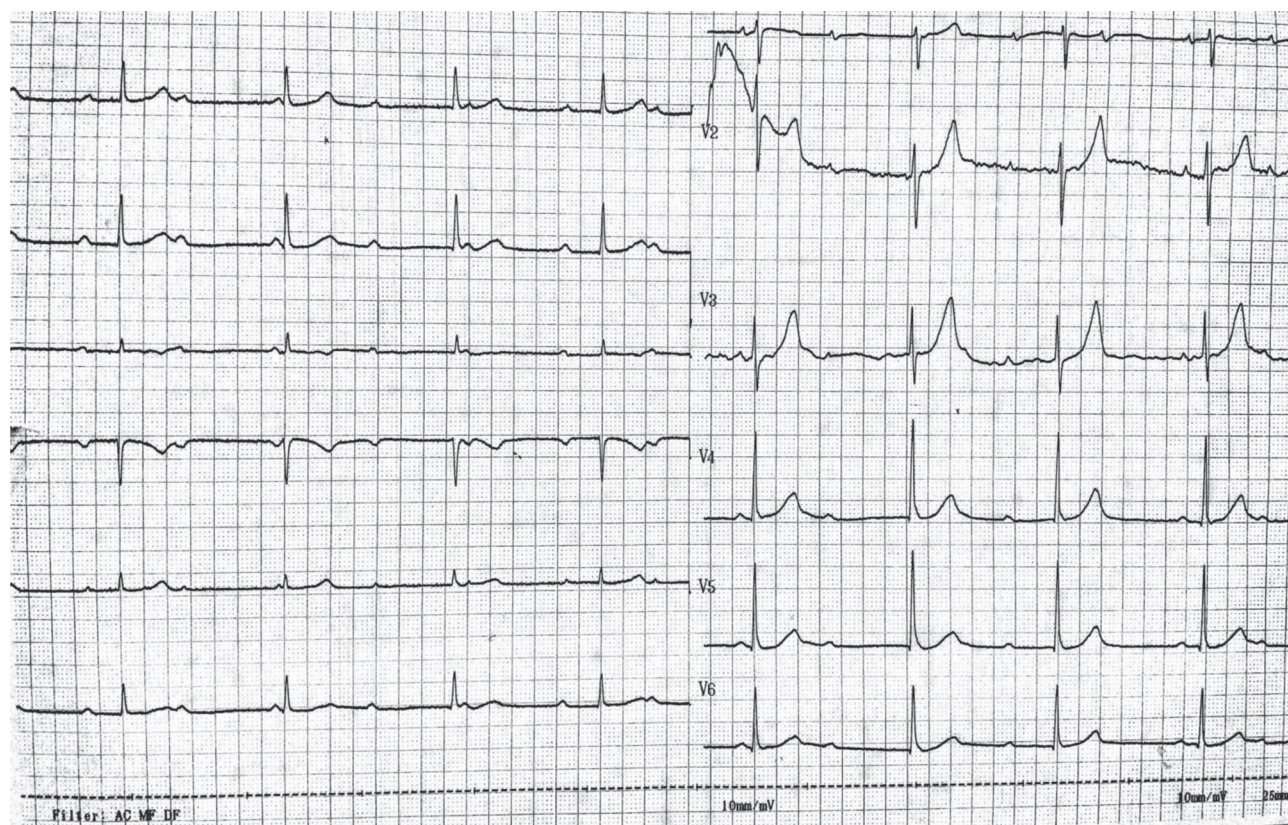


FIGURE 1. Complete atrioventricular block two days before admission to the referral hospital.

HEART BLOCK IN HYPERTHYROIDISM

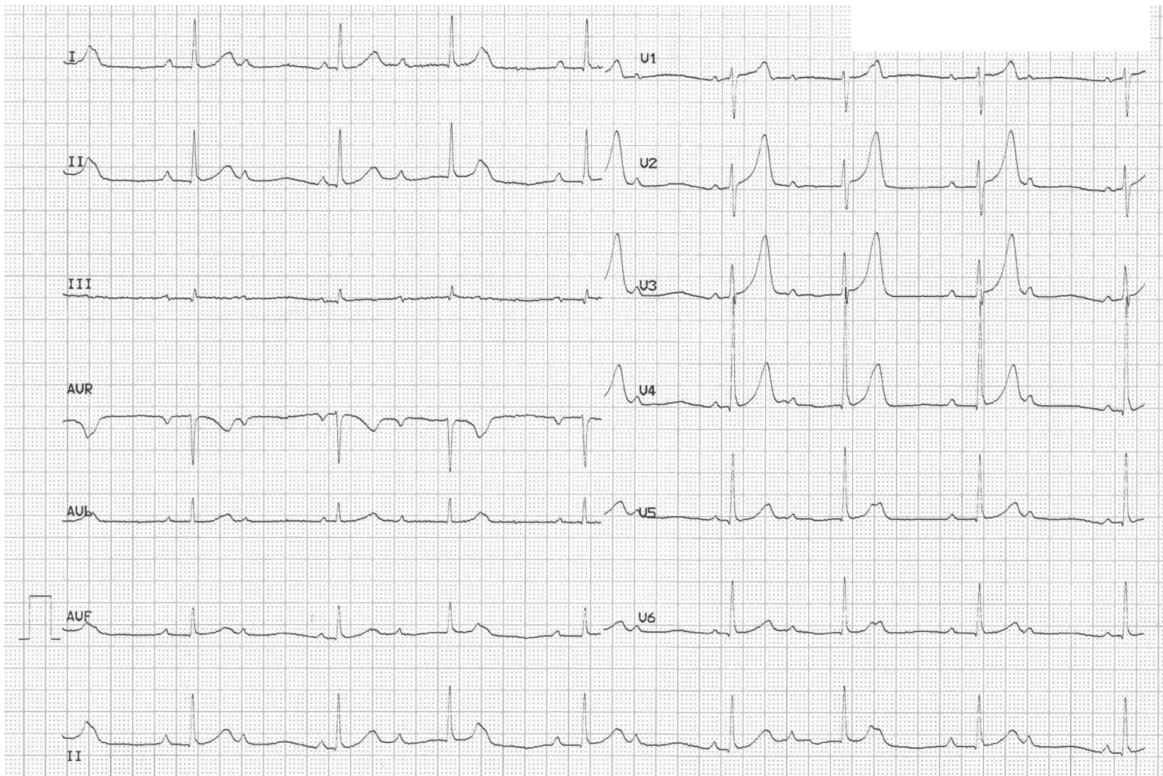


FIGURE 2. Complete atrioventricular block on the ECG performed at the time of submission to the referral hospital.

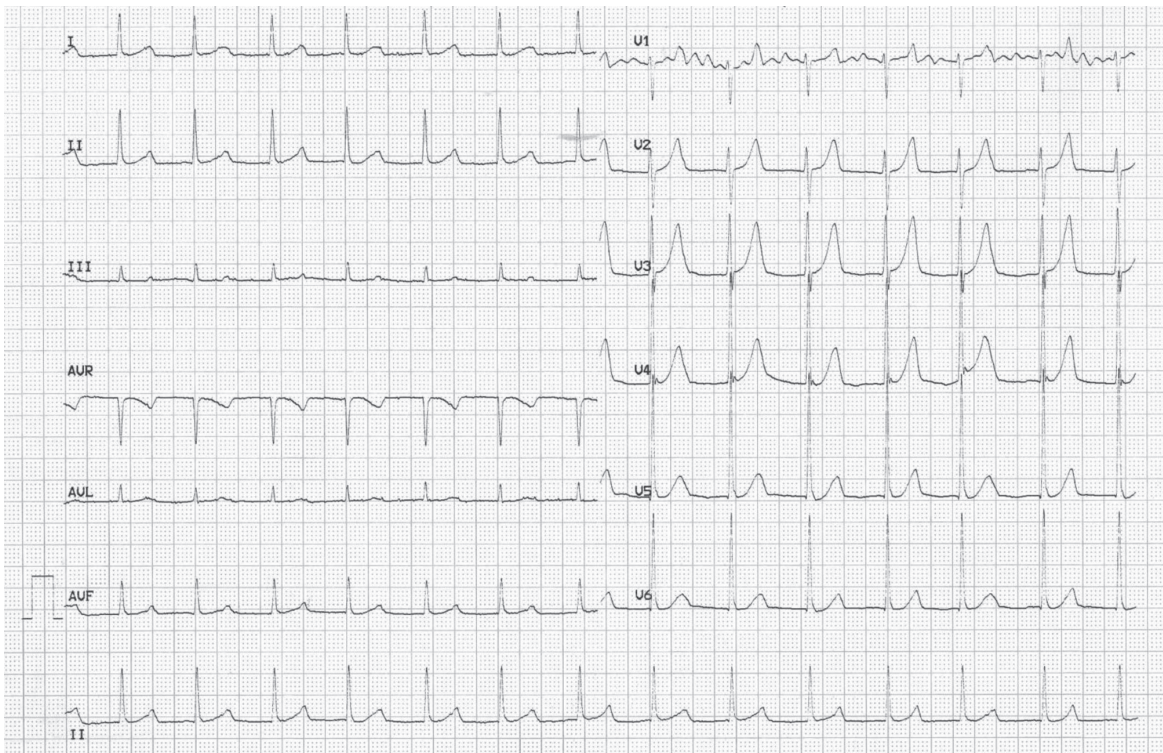


FIGURE 3. Junctional rhythm on the seventh day of hospitalization.

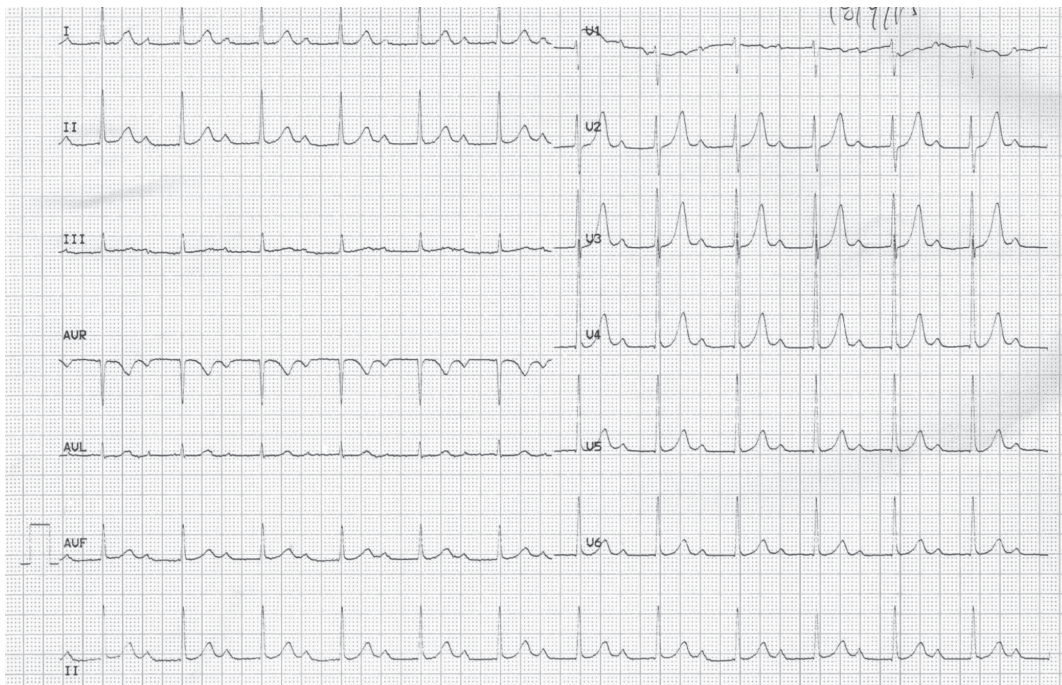


FIGURE 4. First degree atrioventricular block on the ECG performed on the 10th day of hospitalization.

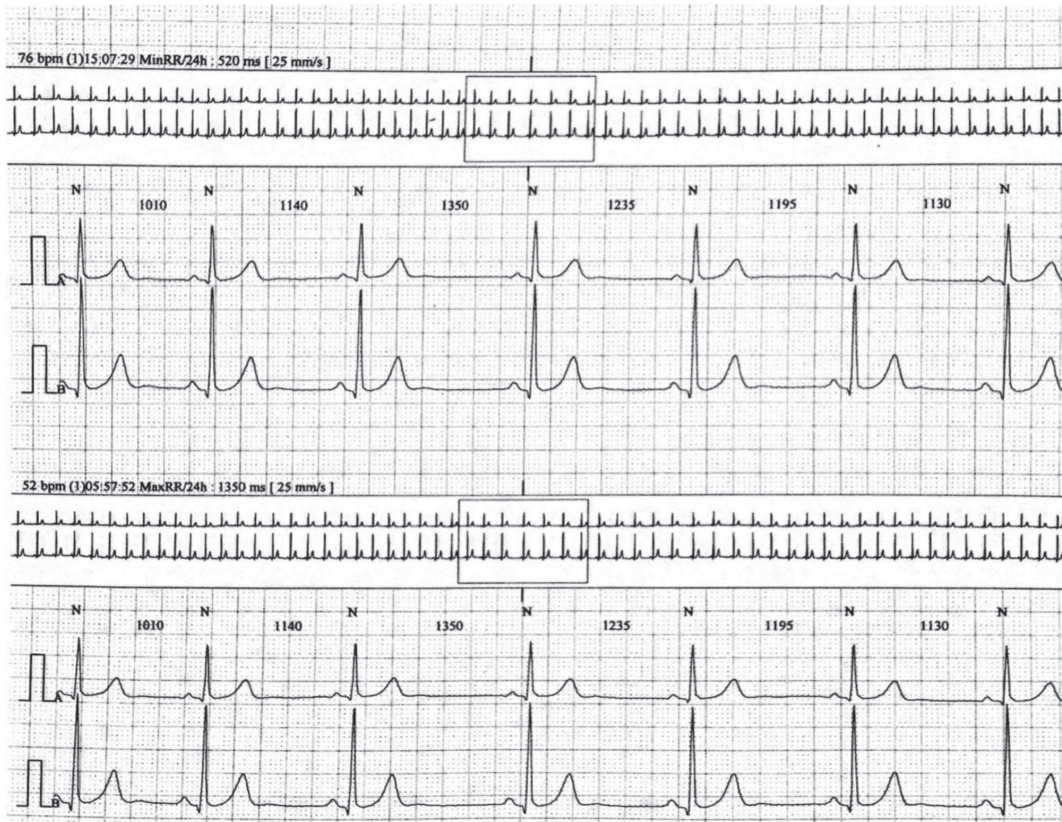

FIGURE 5. Holter recording 3 months after discharge revealed normal sinus rhythm without conduction disturbances.

HEART BLOCK IN HYPERTHYROIDISM

In the present case no signs of infection or electrolyte disturbances were noted, while no drug use with potential negative dromotropic action was reported in the medical history. An autoimmune response could potentially explain the AV conduction disturbance, considering the high levels of antithyroid antibodies. Intensification of antithyroid treatment restored normal conduction. No permanent pacemaker was implanted, despite persistent complete heart block for 8 days in total. We refrained from an electrophysiology assessment as Holter recording on follow up revealed no conduction disturbances.

In conclusion, patients with palpitations and hyperthyroidism should be carefully screened for electrocardiographic evidence of impaired AV conduction. In specific, initiation of beta-blocker therapy in those patients could aggravate their symptoms.

REFERENCES

1. Klein I, Ojamaa K. Thyroid hormone and the cardiovascular system. *N Engl J Med* 2001;344:501-509.
2. Dave JA, Ross IL. Complete heart block in a patient with Graves' disease. *Thyroid* 2008;18:1329-1331.
3. Topaloglu S, Topaloglu OY, Ozdemir O, Soylu M, Demir AD, Korkmaz S. Hyperthyroidism and complete atrioventricular block--a report of 2 cases with electrophysiologic assessment. *Angiology* 2005;56:217-220.
4. Kramer MR, Shilo S, Hershko C. Atrioventricular and sinoatrial block in thyrotoxic crisis. *Br Heart J* 1985;54:600-602.
5. Campus S, Rappelli A, Malavasi A, Satta A. Heart block and hyperthyroidism. Report of two cases. *Arch Intern Med* 1975;135:1091-1095.
6. Muggia AL, Stjernholm M, Houle T. Complete heart block with thyrotoxic myocarditis. Report of a case. *N Engl J Med* 1970;283:1099-1100.
7. Levy DW. Complete heart block complicating thyrotoxicosis. *S Afr Med J* 1973;47:853.
8. Kernoff LM, Rossouw JE, Kennelly BM. Complete heart block complicating thyrotoxicosis. *S Afr Med J* 1974;47:513-515.
9. Sriussadaporn S, Vannasaeng S, Trisukosol D, Nitiyanant W, Piraphatdist T, Vichayanrat A. Complete heart block complicating hyperthyroidism: a case report. *J Med Assoc Thai* 1990;73:53-57.
10. Jalal S, Khan KA, Rauoof MA, et al. Thyrotoxicosis presenting with complete heart block. *Saudi Med J* 2004;25:2057-2058.
11. Ozcan KS, Osmonov D, Erdinler I, et al. Atrioventricular block in patients with thyroid dysfunction: prognosis after treatment with hormone supplementation or antithyroid medication. *J Cardiol* 2012;60:327-332.
12. Sataline L, Donaghue G. Hypercalcemia, heart-block, and hyperthyroidism. *JAMA* 1970;213:1342.
13. Kuo YC, Tseng YT, Lee TI, Hsieh MH. Chronic bifascicular block with intermittent complete atrioventricular block induced by hyperthyroidism. *Int J Cardiol* 2006;110:407-410.
14. Kausel A, Korniyenko A, Sandhu G. Bradyarrhythmia as a presenting feature of subclinical hyperthyroidism. *QJM* 2012;105:461-462.
15. Karakas CY, Topaloglu C, Canbolant E, Seyfeli E, Akgul F. Hyperthyroidism as a rare cause of complete AV block. *Anadolu Kardiyol Derg* 2009;9:67-68.
16. Eraker SA, Wickamasekaran R, Goldman S. Complete heart block with hyperthyroidism. *JAMA* 1978;239:1644-1646.
17. Singer Y, Shvartzman P. [Second degree atrioventricular block in Graves' disease]. *Harefuah* 1999;136:28-9, 95.
18. Almange C, Turmel F, Badoual P, Murie N, Leborgne P. [Hyperthyroidism and atrioventricular heart block (author's transl)]. *Sem Hop* 1978;54:1433-1436.
19. Pitzalis MV, Mastropasqua F, Massari F, et al. Assessment of cardiac vagal activity in patients with hyperthyroidism. *Int J Cardiol* 1998;64:145-151.