

**CARDIOLOGY UPDATE 2006**

## Contemporary Stent Treatment of Coronary Bifurcations

Ioannis Iakovou, MD

*General Army Hospital of Thessaloniki  
& Blue Cross Hospital, Thessaloniki,  
Greece*

**KEY WORDS:** *coronary artery disease;  
coronary angioplasty; coronary stents;  
restenosis; bifurcation lesions*

---

**ABSTRACT**

---

Treatment of coronary bifurcations is a tantalizing problem of interventional cardiology. The introduction of drug-eluting stents (DES) reduced restenosis in the main branch. However, restenosis at the ostium of the side branch remains a problem. While stenting the main branch with provisional side branch stenting seems to be the prevailing approach, in the era of DES various two-stent techniques emerged ("crush") or were re-introduced ("V" or "simultaneous kissing stents", "crush", "T", "culottes", "Y", "Skirt") to allow stenting in the side branch when needed.

Recent advances in percutaneous coronary interventions (PCI) and lately the introduction of drug-eluting stents (DES) have led to a dramatic increase in the number of patients treated percutaneously [1-5]. Bifurcation lesions are one of these complex lesion subsets that are now being confronted more frequently [6,7].

Several studies have shown that bifurcation when compared to non-bifurcation interventions have lower rate of procedural success and higher rate of restenosis [8-10]. Various techniques with use of 1 or 2 stents have been developed to optimize the treatment of this subset of lesions [8-17]. Paradoxically, while stenting of individual lesions has been shown to be superior to balloon angioplasty, stenting of both branches seems to offer no advantage over stenting of the main branch (MB) alone [10].

The recent introduction of DES has resulted in a lower event rate and reduction of main branch restenosis in comparison with historical controls [18]. Up to now, there are only 2 randomized studies and some observational reports that specifically addressed the issue of bifurcational lesion treatment with DES [18-20]. The recently published Sirolimus-eluting stent bifurcational study has given us some important initial direction to structure our approach toward the optimal treatment of bifurcational lesions [18]. This study was a 5-center randomized trial to assess feasibility and safety of treatment of patients with sirolimus-eluting stents (Cypher, Cordis/Johnson & Johnson, Warren, NJ) at true bifurcational lesions (>50% stenosis in both main vessel and ostium of side branch) that enrolled 85 patients (86 lesions). Two different strategies were used: Group A-elective use of two Cypher stents and Group B-the implantation of a single Cypher stent in the main branch with balloon dilatation across the stent struts for the side branch. The protocol allowed the investigators to switch to double stenting if flow impairment or residual ostial stenosis >50% developed in the side branch. Twenty-two out of 43 patients randomized to group B crossed over, resulting in implantation of two stents. The total restenosis rate at 6 months was 25.7%, and it was not significantly different between the double-stenting (28.0%) and the provisional side branch-stenting

*Address for correspondence:*  
Ioannis Iakovou, MD  
Egnatia 119  
54635, Thessaloniki  
Greece  
E-mail: [mailto:iako@hol.gr](mailto:mailto:iako@hol.gr)

(18.7%) groups. The majority of the restenosis cases occurred at the ostium of the side branch and was focal. In the second randomized study (single center, n=91), Pan et al. compared stenting the main branch and balloon dilatation for the side branch to stenting for both branches. Similarly to the previous study there were no statistically significant differences between the 2 strategies [20].

**THROMBOTIC ISSUES AFTER DES IMPLANTATION IN BIFURCATIONS**

Pathological studies have suggested that arterial branch points are foci of low shear and low flow velocity and are sites predisposed to the development of atherosclerotic plaque, thrombus, and inflammation [21-23]. The two or even three layers of struts (with “Crush”) of DES apposed to the vessel wall initially raised concerns about possible increased thrombogenicity. Furthermore, delayed endothelialisation associated with DES may extend the risk of thrombosis beyond 30 days [24]. In the Sirolimus-eluting stent bifurcational study the rate of stent thrombosis was 3.5%. Very recently, we reported a rate of 3.6% of cumulative stent thrombosis after DES implantation in bifurcations in a prospective observational cohort study which included 2229 patients treated with both sirolimus (n=1062 patients) and paclitaxel-eluting stents (n=1167 patients, Taxus, Boston Scientific, Natick, MA) [25]. In this study, bifurcation lesion treatment was identified as independent predictor of subacute (post-procedure to 30 days), late (>30 days), and cumulative thrombosis. However, there were no significant differences regarding the incidence of thrombosis in bifurcations treated with one versus two stents [25].

**PROVISIONAL OR TWO STENTS**

In general, if we take the decision to use 1 stent (at the main branch) there is almost always the possibility to place a second stent on the side branch in case the result is not optimal or adequate. This condition is defined as “provisional stenting”.

In order to decide whether to place 1 stent or 2, we have to consider [1] if the side branch is of adequate size, length, and anatomical distribution suitable to be treated with a stent and [2] if the side branch has a stenosis at the ostium over 50%. If the answer is NO to both questions we will use provisional stenting at the main branch, if YES we will place a second stent at the side branch.

A number of techniques are available with various levels of complexity and indications: the “V”, the “Simultaneous Kissing Stents” (“SKS”), “Crush” and its variations (“reverse” and “step”), “T” and its variation (“modified”), “Culottes”,

“Y” and “Skirt”. The most commonly used techniques for 2 stent placement are the first 3 and will be described in detail below.

**THE “V” AND THE “SIMULTANEOUS KISSING STENTS” TECHNIQUE**

The “V” technique includes the delivery and implantation of 2 stents together. One stent is advanced in the side branch, the other in the main branch, and the 2 stents touch each other forming a proximal carina (Figure 1) [26,27]. When this carina extends to a considerable length (usually 5 mm or more) into the main vessel then this technique is denominated as “SKS” [28]. The type of lesions we consider most suitable for this technique are very proximal lesions such as bifurcation lesions located at the left main stem with a left main artery which is short or free of disease. Ideally the angle between the two branches should be less than 90°. The “V” technique is also suitable for other bifurcations provided the portion of the vessel proximal to the bifurcation is free of disease and there is no need to deploy a stent more proximally.

Pros: The main advantage of these techniques is that the access to any of the 2 branches is never lost. In addition, when a final kissing (FK) inflation is performed there is no need to recross any stent.

Cons: When using these techniques a metallic neocarina is

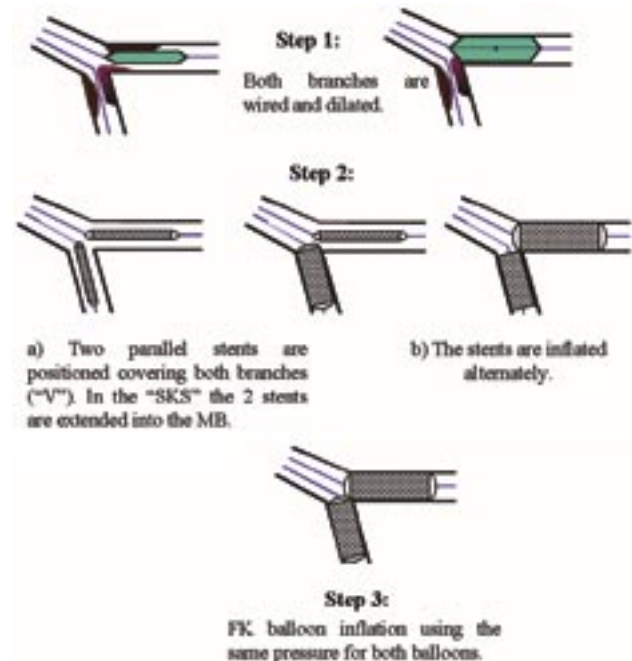


FIGURE 1. The “V” and “Simultaneous Kissing Stents” Stenting Technique. (Abbreviations: FK= Final Kissing, MB= Main Branch, SKS= Simultaneous Kissing Stents).

created within the vessel proximal to the bifurcation. Theoretical concerns about the risk of thrombosis related to this new carina have not been confirmed in our and other operators' experience [19,29]. It is quite intuitive how problematic may be the need to position a stent proximally to the double barrel. There is an inevitable bias towards one of the two branches and the high likelihood to leave a gap.

---

**THE "CRUSH" TECHNIQUE  
AND ITS VARIATIONS**

---

The "Crush" technique [15] was introduced at the time of DES introduction and is described schematically in Figure 2. Two stents are placed in the main branch and the side branch with the former more proximally than the latter. The stent of the side branch will be deployed and its balloon and wire will be removed. The stent subsequently deployed in the main branch will flatten the protruding cells of the side branch stent hence the denomination "Crushing" or "Crush". Wire re-crossing and dilatation of the side branch with a balloon of at least equal diameter with the stent [30], and then FK balloon inflation is recommended. The implementation of FK balloon inflation is done in order to allow better strut contact against the ostium of the side branch and therefore better drug deliv-

ery [19,30]. The "Crush" technique became therefore a sort of simplified "Culottes" technique. After the implementation of the FK inflation as part of the refinement of the technique, restenosis at the ostium of the side branch seems to decrease. The positive aspect is that whenever restenosis occurs, this narrowing is very focal (less than 5 mm in length) and most of the times not associated with symptoms or ischemia. An important element to keep in mind when planning to perform the "Crush" technique is that the two available DES will reach different maximal opening of their cells [19,29]. The maximal cell diameter will be 3.0 mm for the Cypher stent and 3.7 mm for the Taxus stent. This data should be kept in mind when the side branch has a diameter over 3.0 mm.

**Pros:** The main advantage of the "Crush" technique is that the immediate patency of both branches is assured. This gain is important when the side branch is functionally relevant or difficult to be wired. In addition provides excellent coverage of the ostium of the side branch, which is the main disadvantage of the simpler "T" technique (see below).

**Cons:** The main disadvantage is that the performance of the FK balloon inflation makes the procedure more laborious due to the need to re-cross multiple struts with a wire and a balloon.

The main variations of the "classic Crush" technique are the "reverse" and the "step Crush" which can both be performed utilizing a 6 F guiding catheter.

---

**"T" TECHNIQUE**

---

The classic "T" technique consists in positioning a stent first at the ostium of the side branch being careful to avoid the stent protrusion in the main branch (Figure 3). Some operators leave a balloon in the main branch to help to further locate the main branch. Following deployment of the stent and removal of the balloon and the wire from the side branch, a second stent is advanced in the main branch. A wire is then re-advanced into the side branch and FK balloon inflation is performed.

**Pros:** It is less laborious than "Crush". Unlike the "V" it can be used for the coverage of proximal to bifurcation lesions.

**Cons:** In almost all of the cases, this technique will lead to incomplete coverage of the ostium of the side branch. At the present time in our practice, the above technique has been abandoned, and now there are 2 reasons to perform the "T" technique: 1) to place a stent at the ostium of a side branch following placement of a stent in the main branch because the result at the side branch ostium was evaluated as unsatisfactory (provisional side branch stenting), 2) to perform stenting at the ostium of the side branch when there is isolated side branch ostial stenosis.

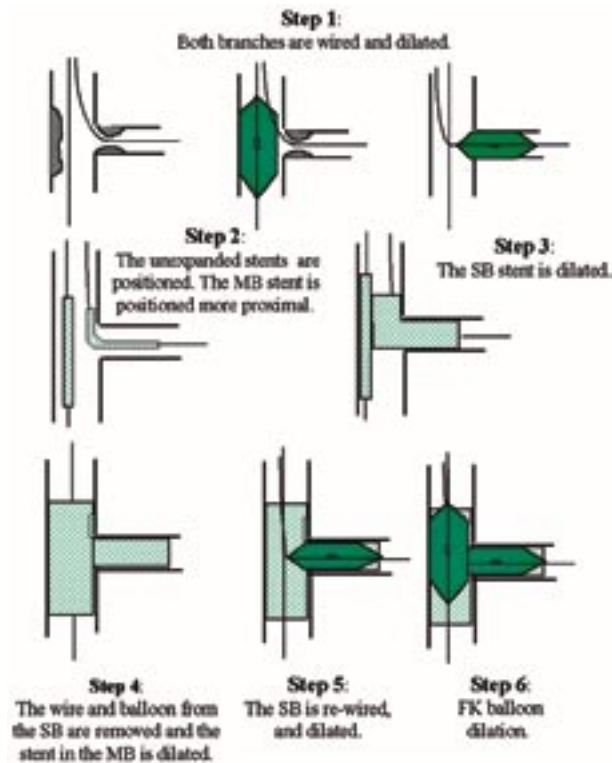


FIGURE 2. "Crush" technique (Abbreviations: FK= Final Kissing, MB= Main Branch, SB= Side branch).

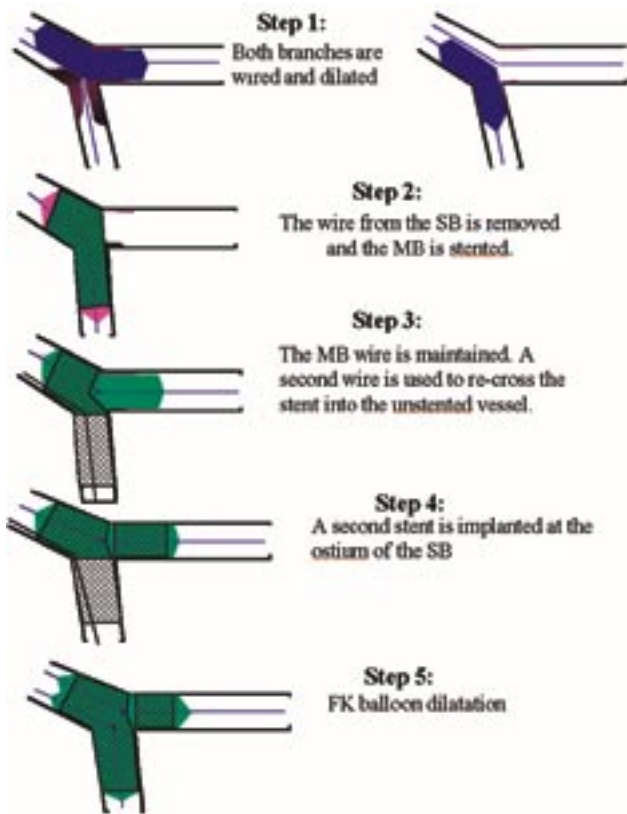


FIGURE 3. The “T” Stenting Technique (through the stent). (Abbreviations: FK= Final Kissing, MB= Main Branch, SB= Side branch).

### CONCLUSIONS

With the use of DES the restenosis at the ostium of the side branch is single digit and the restenosis in the side branch, when it occurs it is most of the times focal. When the side branch is not severely diseased, implantation of a stent in the main branch and provisional stenting in the side branch is the preferred strategy. Implantation of 2 stents as initial approach is appropriate when both branches are significantly diseased (diameter stenosis >50%) and suitable for stenting. A number of techniques are available with various levels of complexity and indications: the “V”, simultaneous kissing stent (SKS), “Crush”, “T”, “Culottes”, “Y”, and “Skirt”.

### REFERENCES

1. Colombo A, Iakovou I. Ten years of advancements in interventional cardiology. *J Endovasc Ther* 2004; 11(Suppl 2):II10-II18.
2. Colombo A, Iakovou I. Drug-eluting stents: the new gold standard for percutaneous coronary revascularisation. *Eur Heart J*

- 2004; 25:895-7.
3. Iakovou I, Ge L, Michev I, et al. Clinical and angiographic outcome after sirolimus-eluting stent implantation in aorto-ostial lesions. *J Am Coll Cardiol* 2004; 44:967-71.
4. Iakovou I, Sangiorgi GM, Stankovic G, et al. Effectiveness of sirolimus-eluting stent implantation for treatment of in-stent restenosis after brachytherapy failure. *Am J Cardiol* 2004; 94: 351-4.
5. Cohen DJ, Bakhai A, Shi C, et al. Cost-effectiveness of sirolimus-eluting stents for treatment of complex coronary stenoses: results from the Sirolimus-Eluting Balloon Expandable Stent in the Treatment of Patients With De Novo Native Coronary Artery Lesions (SIRIUS) trial. *Circulation* 2004; 110:508-14.
6. Iakovou I, Ge L, Colombo A. Contemporary stent treatment of coronary bifurcations. *J Am Coll Cardiol* 2005; 46:1446-55.
7. Iakovou I, Colombo A. Two-stent techniques for the treatment of coronary bifurcations with drug-eluting stents. *Hellenic J Cardiol* 2005; 46:188-98.
8. Al Suwaidi J, Berger PB, Rihal CS, et al. Immediate and long-term outcome of intracoronary stent implantation for true bifurcation lesions. *J Am Coll Cardiol* 2000; 35:929-36.
9. Chevalier B, Glatt B, Royer T, Guyon P. Placement of coronary stents in bifurcation lesions by the “culotte” technique. *Am J Cardiol* 1998; 82:943-9.
10. Yamashita T, Nishida T, Adamian MG, et al. Bifurcation lesions: two stents versus one stent--immediate and follow-up results. *J Am Coll Cardiol* 2000; 35:1145-51.
11. Pan M, Suarez de Lezo J, Medina A, et al. A stepwise strategy for the stent treatment of bifurcated coronary lesions. *Catheter Cardiovasc Interv* 2002; 55:50-7.
12. Ormiston JA, Webster MW, Ruygrok PN, Stewart JT, White HD, Scott DS. Stent deformation following simulated side-branch dilatation: a comparison of five stent designs. *Catheter Cardiovasc Interv* 1999; 47:258-64.
13. Fort S, Lazzam C, Schwartz L. Coronary ‘Y’ stenting: a technique for angioplasty of bifurcation stenoses. *Can J Cardiol* 1996; 12:678-82.
14. Kobayashi Y, Colombo A, Akiyama T, Reimers B, Martini G, di Mario C. Modified “T” stenting: a technique for kissing stents in bifurcational coronary lesion. *Cathet Cardiovasc Diagn* 1998; 43:323-6.
15. Colombo A, Stankovic G, Orlic D, et al. Modified T-stenting technique with crushing for bifurcation lesions: immediate results and 30-day outcome. *Catheter Cardiovasc Interv* 2003; 60:145-51.
16. Colombo A. Bifurcational lesions and the “crush” technique: understanding why it works and why it doesn’t—a kiss is not just a kiss. *Catheter Cardiovasc Interv* 2004; 63:337-8.
17. Carrie D, Karouny E, Chouairi S, Puel J. “T”-shaped stent placement: a technique for the treatment of dissected bifurcation lesions. *Cathet Cardiovasc Diagn* 1996; 37:311-3.
18. Colombo A, Moses JW, Morice MC, et al. Randomized study to evaluate sirolimus-eluting stents implanted at coronary bifurcation lesions. *Circulation* 2004; 109:1244-9.
19. Ge L, Airolidi F, Iakovou I, et al. Clinical and Angiographic

- Outcome Following Implantation of Drug-Eluting Stents in Bifurcation Lesions with the Crush Stent Technique: Importance of Final Kissing Balloon Post-dilatation. *J Am Coll Cardiol*; (in press).
20. Pan M, de Lezo JS, Medina A, et al. Rapamycin-eluting stents for the treatment of bifurcated coronary lesions: a randomized comparison of a simple versus complex strategy. *Am Heart J* 2004; 148:857-64.
  21. Glagov S, Zarins C, Giddens DP, Ku DN. Hemodynamics and atherosclerosis. Insights and perspectives gained from studies of human arteries. *Arch Pathol Lab Med* 1988;112:1018-31.
  22. Honda Y, Fitzgerald PJ. Stent thrombosis: an issue revisited in a changing world. *Circulation* 2003; 108:2-5.
  23. Farb A, Burke AP, Kolodgie FD, Virmani R. Pathological mechanisms of fatal late coronary stent thrombosis in humans. *Circulation* 2003; 108:1701-6.
  24. Virmani R, Guagliumi G, Farb A, et al. Localized hypersensitivity and late coronary thrombosis secondary to a sirolimus-eluting stent: should we be cautious? *Circulation* 2004; 109: 701-5.
  25. Iakovou I, Schmidt T, Bonizzoni E, et al. Incidence, Predictors, and Outcome of Thrombosis after Successful Implantation of Drug-Eluting Stents. *JAMA* 2005; 293:2126-3026.
  - Schampaert E, Fort S, Adelman AG, Schwartz L. The V-stent: a novel technique for coronary bifurcation stenting. *Cathet Cardiovasc Diagn* 1996; 39:320-6.
  27. Colombo A, Gaglione A, Nakamura S, Finci L. "Kissing" stents for bifurcational coronary lesion. *Cathet Cardiovasc Diagn* 1993; 30:327-30.
  28. Sharma SK, Choudhury A, Lee J, et al. Simultaneous kissing stents (SKS) technique for treating bifurcation lesions in medium-to-large size coronary arteries. *Am J Cardiol* 2004; 94: 913-7.
  29. Ge L, Tsalalou E, Iakovou I, et al. In-Hospital And 9-Month Outcome Of Treatment Of Coronary Bifurcational Lesions With Sirolimus-Eluting Stents. *Am J Cardiol*; (in press).
  30. Ormiston JA, Currie E, Webster MW, et al. Drug-eluting stents for coronary bifurcations: insights into the crush technique. *Catheter Cardiovasc Interv* 2004; 63:332-6.